

April, 2021; (August, 2021 - updated pages: 57-62; 64-68; 125);
(December 2021: - updated page 124); (January 2022: updated page 64-69)

THE MEDICAL MANAGEMENT OF FIBRODYSPLASIA OSSIFICANS PROGRESSIVA: CURRENT TREATMENT CONSIDERATIONS



From The International Clinical Council on FOP (ICC) & Consultants:

Frederick S. Kaplan, Mona Al Mukaddam, Genevieve Baujat, Matthew Brown, Amanda Cali, Tae-Joon Cho, Corrie Crowe, Carmen L. De Cunto, Patricia Delai, Robert J. Diecidue, Maja Di Rocco, Elisabeth M.W. Eekhoff, Clive Friedman, Zvi Grunwald, Nobuhiko Haga, Edward C. Hsiao, Richard Keen, Joseph Kitterman, Charles Levy, Rolf Morhart, J. Coen Netelenbos, Christiaan Scott, Eileen M. Shore, Michael A. Zasloff, Keqin Zhang, Robert J. Pignolo

Corresponding Editors:

Frederick S. Kaplan, M.D.
Isaac and Rose Nassau Professor of Orthopaedic Molecular Medicine
Director, Center for Research in FOP & Related Disorders
The Perelman School of Medicine - The University of Pennsylvania
Department of Orthopaedic Surgery
3737 Market Street – Sixth Floor
Philadelphia, PA 19104, USA
Tel: (office) 215-294-9145
Fax: 215-222-8854
Email: Frederick.kaplan@penmedicine.upenn.edu

Robert J. Pignolo, M.D., Ph.D.
Chair, Division of Geriatric Medicine & Gerontology
Robert and Arlene Kogod Professor of Geriatric Medicine
Mayo Clinic College of Medicine
200 First Street SW
Rochester, MN 55905, USA
Tel: 507-293-6988; Secretary: 507-293-0813
Fax: 507-293-3853
Email: pignolo.robert@mayo.edu

Cite: [Kaplan FS, et al. The medical management of fibrodysplasia ossificans progressiva: current treatment considerations. **Proc Intl Clin Council FOP** 2: 1-128, 2021]

Contents

I. ABSTRACT	4
II. EXECUTIVE SUMMARY OF KEY PRACTICE POINTS	5
III. THE CLINICAL AND BASIC SCIENCE BACKGROUND OF FOP	10
1. INTRODUCTION	10
2. CLASSIC CLINICAL FEATURES OF FOP	10
3. OTHER SKELETAL ANOMALIES OF FOP	13
4. RADIOGRAPHIC FEATURES OF FOP	14
5. PATHOLOGY OF FOP LESIONS.....	15
6. LABORATORY FINDINGS IN FOP.....	16
7. ETIOLOGY & PATHOGENESIS OF FOP.....	17
8. FOP VARIANTS	20
9. THE IMMUNE SYSTEM & FOP	20
10. EPIDEMIOLOGIC, GENETIC & ENVIRONMENTAL FACTORS IN FOP	21
11. GENETIC TESTING & FOP	22
12. ANIMAL MODELS OF FOP	22
13. SUPPORTIVE TREATMENT IN FOP	24
14. PROGNOSIS OF FOP.....	25
15. CHALLENGES OF THERAPEUTIC ASSESSMENT IN FOP	25
IV. THE PATHOLOGIC AND PATHOPHYSIOLOGIC-BASED TREATMENT OF FOP	27
1. INTRODUCTION	27
2. CORTICOSTEROIDS IN FOP	27
3. CYCLO-OXYGENASE-2 (COX-2) INHIBITORS & NSAIDS IN FOP	30
4. TOPICAL ANALGESICS IN FOP.....	32
5. MAST CELL INHIBITORS IN FOP	33
6. BISPHOSPHONATES IN FOP	35
7. IMATINIB IN FOP.....	41
8. MUSCLE RELAXANTS IN FOP	42
9. CHEMOTHERAPY AGENTS & RADIATION THERAPY IN FOP	43
10. BONE MARROW TRANSPLANTATION IN FOP.....	43
11. MISCELLANEOUS AGENTS & APPROACHES IN FOP	44
12. DEFINITIVE THERAPEUTIC TARGETS IN FOP	45
V. SPECIAL MEDICAL CONSIDERATIONS IN FOP	49
1. INTRODUCTION	49
2. INJURY PREVENTION IN FOP	49
3. SCALP NODULES IN FOP	50
4. SPINAL DEFORMITY IN FOP	51
5. CARDIOPULMONARY FUNCTION IN FOP	52
6. RESPIRATORY HEALTH IN FOP	55
7. IMMUNIZATIONS FOR DISEASES OTHER THAN INFLUENZA IN FOP	57
8. IMMUNIZATIONS FOR INFLUENZA IN FOP.....	62
9. CORONAVIRUS (COVID-19) PRECAUTIONS & GUIDANCE FOR FOP PATIENTS & FAMILIES.....	64
10. ACUTE & CHRONIC PAIN MANAGEMENT IN FOP.....	69
11. DIFFERENTIAL DIAGNOSIS OF HIP PAIN IN FOP.....	73
12. LIMB SWELLING IN FOP	74
13. PRESSURE ULCERS IN FOP	75
14. DERMATOLOGY & FOP	76
15. FRACTURES & DISLOCATIONS IN FOP.....	79
16. NUTRITION, CALCIUM & VITAMIN D GUIDELINES IN FOP	80
17. PREVENTIVE ORAL HEALTHCARE IN FOP.....	81
18. ORTHODONTICS & FOP	84
19. SUBMANDIBULAR FLARE-UPS IN FOP.....	85
20. DENTAL ANESTHESIA IN FOP	86

21. GENERAL ANESTHESIA IN FOP.....	89
22. ACCEPTABLE/LOW RISK PROCEDURES IN FOP.....	92
23. NEUROLOGICAL ISSUES IN FOP.....	93
24. HEARING IMPAIRMENT IN FOP.....	94
25. GASTROINTESTINAL ISSUES IN FOP.....	94
26. KIDNEY STONES & FOP.....	95
27. REHABILITATION ISSUES IN FOP.....	96
28. AIDS, ASSISTIVE DEVICES, AND ADAPTATIONS (AADAS).....	98
29. PREGNANCY ISSUES IN FOP.....	103
30. FOP VARIANTS.....	105
VI. CURRENT TREATMENT CONSIDERATIONS	108
VII. CLASSES OF MEDICATIONS (TABLE 1)	110
CLASS I MEDICATIONS.....	110
CLASS II MEDICATIONS	112
CLASS III MEDICATIONS.....	115
VIII. EMERGENCY GUIDELINES FOR 1ST RESPONDERS, PHYSICIANS & DENTISTS.....	116
IX. CONCLUSIONS	119
X. ACKNOWLEDGMENTS	120
XI. CONFLICTS OF INTEREST DECLARATION.....	121
XII. AUTHORS' CONTACT INFORMATION.....	122
FIGURE 1. TARGETS & POTENTIAL TREATMENTS FOR FOP.....	128

This version of the FOP Guidelines, written in English, is the only version reviewed and endorsed by the ICC. The ICC acknowledges that this document may be freely translated into other languages, but does not guarantee the accuracy of any such translations. To the extent possible, any translation of the FOP Guidelines should be performed and reviewed by bilingual medical experts from the country where the translation is intended to be used.

I. ABSTRACT

Fibrodysplasia ossificans progressiva (FOP) is a rare, disabling genetic condition characterized by congenital malformations of the great toes and progressive heterotopic ossification (HO) in specific anatomic patterns. FOP is the most catastrophic disorder of HO in humans. Flare-ups are episodic; immobility is cumulative.

A common mutation in activin receptor IA (ACVR1), a bone morphogenetic protein (BMP) type I receptor, exists in all sporadic and familial cases with a classic presentation of FOP.

Approximately 97% of individuals with FOP have this recurrent mutation. Approximately 3% of affected individuals have a variant mutation in ACVR1, but all individuals with FOP have mutations in the ACVR1 gene.

The discovery of the FOP gene established a critical milestone in understanding FOP, revealing a highly conserved therapeutic target in the BMP signaling pathway, and propelling approaches for developing novel inhibitors of ACVR1-mediated BMP signaling. While effective therapies for FOP will likely be based on interventions that modulate overactive ACVR1 signaling or specifically block postnatal HO, present management is focused on early diagnosis, assiduous avoidance of injury or iatrogenic harm, symptomatic amelioration of painful flare-ups, and optimization of residual function.

Here, we briefly review the clinical and basic science background of FOP, the scientific basis for the use of various medications, special medical considerations, and guidelines for the symptomatic relief of FOP based upon currently available knowledge. This report is not intended to present a specific approach for managing the symptoms of FOP, but rather is intended to present views, statements, or opinions of the authors that may be helpful to others who face similar challenges.

Further advances in therapeutics will be based on knowledge of disease mechanisms at the molecular and cellular level, the refinement of genetically-based animal models for drug testing, and rigorous clinical trials to assess novel and emerging treatment and prevention strategies.

II. EXECUTIVE SUMMARY OF KEY PRACTICE POINTS

Methods

Twenty-one ICC members and five consultants from 14 countries, chosen for their clinical expertise in FOP, collaborated to develop this summary statement. Participants included anesthesiologists, endocrinologists, rheumatologists, orthopaedic surgeons, clinical geneticists, molecular geneticists, neonatologists, pediatricians, internists, physiatrists, geriatricians, dermatologists, dentists, oral surgeons and a non-voting representative from a parent support group. All participants completed a conflict-of-interest declaration. The consensus was supported by academic funding, without pharmaceutical support. A modified Delphi-like consensus methodology was adopted (Di Rocco et al., 2017). A comprehensive literature search was conducted using Pub Med and the search terms “fibrodysplasia ossificans progressiva.” Additional relevant articles on FOP were also identified by Pub Med searches when supplementary information was necessary. A comprehensive review of >2500 articles formed the basis of discussion by the Publications Committee of the ICC. Preparations for the consensus took place over 12 months, including two preparatory meetings and regular teleconference discussions between the working group members. In addition, recommendations were incorporated for widespread consideration from Di Rocco et al., 2017 and Hsiao et al., 2019. At the final consensus meeting, propositions and recommendations were considered by participants and discussed in plenary session enabling reformulation of the recommendations, if necessary. As FOP is an ultra-rare condition, evidence-based statements are generally moderate to low. If published data were unavailable or insufficient, experts’ clinical experiences and opinions were considered. Finally, all clinical experts ratified the executive summary. All revisions were conducted with the same standards.

General Recommendations:

1. The diagnosis of FOP is clinical (skeletal malformations including malformed great toes; soft tissue swelling and progressive heterotopic ossification (HO), but requires genetic confirmation (ACVR1 gene mutation). If FOP is suspected, all elective procedures such as surgeries, biopsies, and immunizations should be deferred until a definitive diagnosis is made.
2. Each patient should have a primary physician who is willing to consult with an FOP expert and help coordinate a local care team.
3. Patients and their families should be informed about the International Clinical Council on FOP (ICC), the International FOP Association (IFOPA), and country-specific support groups at the time of diagnosis.

Activities: Activity is encouraged at all ages, but passive range of motion (motion performed by someone other than the patient) must be avoided. Singing, water exercises, and activities for respiratory health are encouraged.

Avoid soft tissue injuries, contact sports, overstretching of soft tissues, muscle fatigue, biopsies, removal of heterotopic bone and all non-emergent surgical procedures.

Anesthesia: An expert anesthesiologist experienced in general anesthesia for FOP patients must be consulted pre-operatively in all cases. If general anesthesia is required, an awake intubation by nasotracheal fiber-optic technique should be performed because of the neck malformations, jaw motion limitations, sensitive airway and risk of an obstructing neck flare. Highly-skilled FOP-aware anesthesiologists should be present for all elective intubations.

Covid-19: Please see section V.9 and ICC and IFOPA websites (www.iccfop.org & www.ifopa.org) for latest updates.

Falls: Locked upper limbs may accentuate head and neck trauma from falls. Epidural hematomas are common (surgical emergency). Consider protective headgear in children who have upper limb involvement. All head and neck injuries should be evaluated immediately on an emergent basis.

Flare-up: (Back/chest): Consider non-steroidal anti-inflammatory medications or COX-2 inhibitors (oral or topical) with GI precautions. Use analgesics, muscle relaxants, and local applications of ice packs, as needed. Avoid narcotic analgesia.

Flare-ups: (Limbs/throat/submandibular): Patients can present with inflammatory flare-ups with significant swelling and inflammation. These symptoms can be highly variable between patients and events. Prednisone – 2 mgs/kg once daily (up to 100 mgs daily) in AM (per oral) for four days (or equivalent corticosteroid); begin as early as possible after the onset of flare-up signs and symptoms. Keep prednisone on-hand as “pill-in-pocket” approach for emergencies. Alternatively, Pulse IV steroids may be used as directed. Avoid corticosteroids, if possible, for axial flares. Use oral and/or topical NSAID analgesics and/or muscle relaxants, as needed, with assiduous GI precautions. Local application of cool packs may also be helpful. Avoid narcotic analgesia whenever possible. FOP experts should be consulted with all submandibular flare-ups and the detailed guidelines should be assiduously followed.

Flare-ups (Prophylaxis): Flare-ups often result from over-use and soft tissue injuries. Prednisone - 1-2 mgs/kg, (per oral) once daily for 3-4 days to prevent flare-up after severe soft-tissue injury. Do not use after minor bumps or bruises. Use prednisone prophylactically as directed for dental or surgical procedures.

Fractures: Fractures can occur in both normotopic and heterotopic bone, and usually heal normally without much heterotopic bone if treated conservatively. An FOP expert in fracture management should be consulted in all cases.

Gastrointestinal Issues: Many patients with FOP report frequent nausea and vomiting. The cause and significance of this is unknown. Gastrointestinal complaints should be investigated to rule-out more serious conditions.

Hearing: Conductive hearing impairment is common in FOP. FOP patients should be screened in childhood by audiometry for hearing impairment. Hearing aids may improve severe conductive hearing loss.

Immunizations: Immunization by subcutaneous administration is recommended for all vaccines that can be administered by that route. Avoid all intramuscular immunizations and intra-nasal influenza immunizations with live or attenuated viruses as they may precipitate flare-ups of FOP. There have been no reported cases of flare-ups following subcutaneous immunization with the MMR or MMRV vaccines despite the fact that they contain attenuated viruses. Immunizations should not be given during flare-ups and should be avoided until 6-8 weeks after flare-ups resolve. All household contacts should be immunized against pertussis and COVID-19. At this time, the ICC is unable to recommend for or against the COVID vaccine for patients with FOP. Consult detailed immunization guidelines and updates on the ICC and IFOPA websites (www.iccfop.org & www.ifopa.org).

Influenza: Administer influenza vaccines subcutaneously, but never during flare-ups. Wait until 6-8 weeks after a flare-up has resolved before administering influenza vaccine. Avoid live attenuated flu vaccine as it may cause flu-like symptoms and precipitate flare-ups of FOP. Household contacts of FOP patients should

be immunized annually. Consider anti-viral therapy if flu symptoms occur. Consult detailed influenza immunization guidelines as recommendations may change annually.

Injuries: The prevention of flare-ups and heterotopic bone formation involves multimodal approaches. This includes the recognition and avoidance of known causes of flare-ups (contact sports, soft tissue injuries, blunt muscle trauma, muscle fatigue, muscle stretching, intramuscular injections and immunizations, biopsies, removal of heterotopic bone, all non-emergent surgical procedures and viral illnesses).

IVs: Patients with FOP can tolerate peripheral blood collection and IVs when performed by an experienced phlebotomist. It is critical that the procedure be performed in as gentle and minimally-invasive manner as possible. Tourniquet time should be minimized. Consultation with clinicians who are familiar with the care of FOP patients is essential. Superficial IV access and venipuncture is acceptable. Traumatic IV's must be avoided. Central lines, PICC lines, and arterial punctures may cause HO and must be avoided unless critical for the patient's medical management.

Kidney Stones: There is a three-fold greater risk of kidney stones in FOP. Encourage fluid intake (preferably water) of 1.5-2 liters/day, and avoidance of high protein and high salt diets. Age- and sex-based recommended daily allowances for calcium should be maintained.

Limb Swelling: Lymphedema and transient neuropathy may occur with flare-ups of limbs. Elevate legs while sleeping and recumbent, whenever possible. Take one low-dose aspirin daily with food for DVT prophylaxis, if indicated. Rule-out deep vein thrombosis with Doppler ultrasound. Use fitted support stockings for chronic lymphedema (but avoid traumatic compression). Lymphedema therapy may be helpful for chronic lymphedema.

Medications:

Corticosteroids

1. Steroid prophylaxis is recommended for significant blunt muscle trauma.
2. Steroid prophylaxis is recommended for dental and surgical procedures.
3. Steroid treatment should be considered for the symptomatic relief of emergent flare-ups of the limbs, jaw and submandibular area.

COX-2 Inhibitors & NSAIDs

There is no definitive evidence that chronic treatment with COX-2 inhibitors or NSAIDs prevents or ameliorates flare-ups in FOP. However, COX-2 inhibitors or oral/topical NSAIDs may be helpful for symptomatic management of flare-ups and chronic arthropathy when corticosteroids are not indicated.

Bisphosphonates

There is no definitive evidence that bisphosphonates prevent or ameliorate flare-ups in FOP. However, intravenous bisphosphonates may be considered for the prevention of steroid-associated bone loss. Dentists should be made aware of any prior bisphosphonate use.

Imatinib

There is no definitive evidence that imatinib prevents or ameliorates flare-ups in FOP. However, early clinical observations support the implementation of clinical trials of imatinib in children with uncontrolled FOP flare-ups.

Chemotherapy Agents & Radiation Therapy

There is no evidence of efficacy with these agents. The use of these approaches is contraindicated in the management of FOP.

Bone Marrow Transplantation

This approach is ineffective and contraindicated in the treatment of FOP.

Miscellaneous Agents in FOP

The chronic use of antiangiogenic agents, calcium binders, colchicine, fluoroquinolone antibiotics, propranolol, mineralization inhibitors, PPAR-gamma antagonists and TNF- α inhibitors currently have no role in the management of FOP.

Definitive Therapeutic Targets in FOP

Much of the worldwide collaborative research effort in FOP is focused here, and detailed accounts of the work and progress can be found on www.clinicaltrials.gov, in the Twenty-Seventh Annual Report of the FOP Collaborative Research Project (Kaplan, Al Mukaddam, Shore et al., 2018), as well as in recent reviews. Patients should be informed about ongoing clinical trials.

Mental Health: If clinical evaluation suggests depression, psychological support is recommended. Family therapy may be helpful.

Neurological Issues: Patients with FOP have reported a higher incidence of neurological symptoms including pain both during and remote from an FOP flare-up. The sources of pain should be carefully explored. Some individuals with FOP report chronic headaches. If headaches persist, patients should be referred to a neurologist, who can make recommendations for treatment.

Nutrition: In cases of ankylosis of the jaw, a dietician should be consulted to ensure adequate nutrition.

Occupational Therapy (OT): Occupational therapy, focused on enhancing activities of daily living may be useful to improve the quality of life of FOP patients. Perform periodic OT evaluations for assistive devices as activities of daily living change.

Orthodontics: Routine orthodontic care has not been reported to cause flare-ups of FOP. However, all FOP patients seeking orthodontic care should consult with an FOP dental expert.

Physical Therapy (PT): Passive range of motion is strictly prohibited. Warm water hydrotherapy may be helpful.

Pregnancy: Although pregnancy with FOP is possible, FOP poses major life-threatening risks to mother and child as well as life altering consequences to the entire family if a child is born with this condition.

Pregnancy in FOP should never be undertaken without serious consideration and family planning. Unwanted pregnancies should be assiduously avoided. Independent genetic counseling is available, if desired. Should a pregnancy occur, guidance and care at a high-risk pregnancy center are imperative.

Pressure Ulcers: In patients with limited motion prevention of pressure sores by appropriate methods or devices is recommended. A wound care team should be involved in the care.

Respiratory Health: Singing, swimming and incentive spirometry are encouraged to maintain lung function. Perform baseline pulmonary function tests (PFTs), echocardiogram, chest x-ray and pulse oximetry after four years of age. Repeat periodically. Pulmonary consultation and sleep studies may be helpful in directing specific respiratory therapies. Supplemental oxygen should not be used in an unmonitored setting. In patients with respiratory insufficiency, immunization for influenza and pneumococcal pneumonia should be considered. Please follow immunization guidelines above.

Scalp Nodules: Scalp nodules are common signs of flare-up, especially in children with FOP. Although they can be alarming in size, they often spontaneously regress and are of minimal clinical significance.

School: Use school aides to protect and assist children. Parents can request a medical letter for assistance. Preschool evaluation is helpful. School nurses, staff, and teachers should be aware of the limitations of FOP, and protocols for managing injuries and flare-ups as well as special adaptive needs.

Spinal Deformity: Spinal deformity is common in FOP and can occur independently of flare-ups. Rapid progression of spinal deformity – especially in childhood – should be evaluated by an expert in FOP.

Surgery: Avoid surgery, except in emergencies. Always avoid surgery to remove heterotopic bone.

Teeth: Preventative dental care is essential and should begin at an early age. Avoid sugary sweets and drinks. Avoid mandibular blocks, over-stretching of the jaw, and muscle fatigue. Consult FOP dental experts before any procedure.

References

Di Rocco M, Baujat G, Bertamino M, Brown M, De Cunto CL, Delai PLR, Eekhoff EMW, Haga N, Hsiao E, Keen R, Morhart R, Pignolo RJ, Kaplan FS. International physician survey on management of FOP: a modified Delphi study. **Orphanet J Rare Dis.** Jun 12;12(1):110. doi: 10.1186/s13023-017-0659-4, 2017

Hsiao EC, Di Rocco M, Cali A, Zasloff M, Al Mukaddam M, Pignolo R, Grunwald Z, Netelenbos C, Keen R, Baujat G, Brown MA, Cho TJ, De Cunto C, Delai P, Haga N, Morhart R, Scott C, Zhang K, Diecidue RJ, Friedman CS, Kaplan FS, Eekhoff EMW. Special considerations for clinical trials in fibrodysplasia ossificans progressiva. **Br J Clin Pharmacol.** 85(6): 1199-1207, 2019

III. THE CLINICAL AND BASIC SCIENCE BACKGROUND OF FOP

1. Introduction

Here, we provide a brief summary of the clinical and basic science background of FOP in order to place the treatment considerations that follow into a clinical and scientific context. Comprehensive clinical reviews of FOP are available (Kaplan et al., 2008; Shore & Kaplan, 2010; Kaplan et al., 2013; Pignolo et al., 2013; Huning & Gillessen-Kaesbach, 2014).

References

Huning I & Gillessen-Kaesbach. Fibrodysplasia ossificans progressiva: Clinical course, genetic mutations and genotype-phenotype correlations. **Molec Syndromology** 5: 201-211, 2014

Kaplan FS, Pignolo RJ, Al Mukaddam M, Shore EM. Genetic disorders of heterotopic ossification: fibrodysplasia ossificans progressiva and progressive osseous heteroplasia (chapter 112, pp. 865-870). In Bilezikian J (ed). **Primer on the Metabolic Bone Diseases and Disorders of Mineral Metabolism – Ninth Edition**. The American Society for Bone and Mineral Research, Washington, D.C., 2019

Kaplan FS, LeMerrer M, Glaser DL, Pignolo RJ, Goldsby RE, Kitterman JA, Groppe J, Shore EM. Fibrodysplasia ossificans progressiva. **Best Pract Res Clin Rheumatol** 22: 191-205, 2008

Pignolo RJ, Shore EM, Kaplan FS. Fibrodysplasia ossificans progressiva: diagnosis, management, and therapeutic horizons. In Emerging Concepts in Pediatric Bone Disease. **Pediatric Endocrinology Reviews**. 10(S-2): 437-448, 2013

Shore EM, Kaplan FS. Inherited human disease of heterotopic bone formation. **Nat Rev Rheumatol** 6: 518-527, 2010

2. Classic Clinical Features of FOP

Fibrodysplasia ossificans progressiva (FOP: OMIM #135100) is an ultra-rare heritable disorder of connective tissue characterized by congenital malformations of the great toes, and progressive heterotopic ossification (HO) in characteristic anatomic patterns (Kaplan et al., 2005; Pignolo et al., 2019).

Individuals with FOP appear normal at birth except for characteristic malformations of the great toes that are present in all classically affected individuals (Kaplan et al., 2005; Towler, Kaplan, Shore, 2020; Towler, Peck, Kaplan, Shore, 2020). During the first decade of life, most children with FOP develop episodic, painful inflammatory soft tissue swellings (called flare-ups) (Cohen et al., 1993; Pignolo et al., 2016). These are often mistaken for tumors. Misdiagnosis is common and iatrogenic harm is high (Kitterman et al., 2005; Zaghoul et al., 2008).

While some flare-ups regress spontaneously, most transform soft connective tissues - including aponeuroses, fascia, ligaments, tendons, and skeletal muscles - into mature heterotopic bone. Ribbons, sheets, and plates of heterotopic bone replace skeletal muscles and connective tissues through a process of endochondral ossification that leads to an armament-like encasement of bone and permanent immobility. Minor trauma such as intramuscular immunizations, mandibular blocks

for dental work, muscle fatigue, blunt muscle trauma from bumps, bruises, falls, or influenza-like viral illnesses can trigger painful new flare-ups of FOP leading to progressive HO. Attempts to surgically remove heterotopic bone often provoke explosive and painful new episodes of bone growth (Kaplan et al., 2005).

HO progresses in characteristic anatomic and temporal patterns, typically first occurring in the dorsal, axial, cranial, and proximal regions of the body and later in the ventral, appendicular, caudal, and distal regions. The severe pain that commonly accompanies appendicular flare-ups is often ascribed to compartment syndrome (Kaplan et al., 2020). A unique case recently documented compartment syndrome during an acute flare-up of FOP (Kaplan et al., 2020).

Several skeletal muscles including the diaphragm, intrinsic muscles of the tongue, and extra-ocular muscles are spared from HO in FOP. Cardiac muscle and smooth muscle are notably spared from HO (Cohen et al., 1993; Kaplan et al., 2005; Pignolo et al., 2018).

HO in FOP is episodic, but disability is cumulative. Most patients with FOP are confined to a wheelchair by the third decade of life, and require lifelong assistance in performing activities of daily living (Cohen et al., 1993; Rocke et al., 1994; Kaplan et al., 2018a; Kaplan et al., 2018b). Severe weight loss may result following ankylosis of the jaw. Severe restrictive chest wall disease and decrease in pulmonary function due to developmental arthropathy of the costo-vertebral joints and heterotopic ossification of the chest wall develops early (Towler, Shore, Kaplan, 2020; Botman et al., 2021). Pneumonia or right-sided heart failure may complicate rigid fixation of the chest wall. The severe disability of FOP results in low reproductive fitness. Fewer than ten multigenerational families showing inheritance of FOP are known worldwide. The median age at death is approximately 40 years, but the median estimated life expectancy is 56 years. Death often results from complications of thoracic insufficiency syndrome or pneumonia (Kaplan et al., 2010).

A global, patient-reported registry has been established to characterize the course of disease and track clinical outcomes in patients with FOP. Baseline phenotypes on 299 patients from 54 countries are reported based on aggregate data from the International FOP Association (IFOPA) Global Registry (the "FOP Registry"). Overall, the FOP Registry database provides a useful tool for expanding knowledge of FOP, designing clinical trials and facilitating evidence-based decisions about the optimal monitoring and management of affected individuals (Pignolo et al., 2020).

References

- Botman E, Smilde BJ, Hoebink M, Treurniet S, Raijmakers P, Kamp O, Teunissen BP, Bökenkamp A, Jak P, Lammertsma AA, van den Aardweg JG, Boonstra A, Eekhoff EMW. Deterioration of pulmonary function: An early complication in Fibrodysplasia Ossificans Progressiva. **Bone Rep** 2021 Feb 25;14:100758. doi: 10.1016/j.bonr.2021.100758. PMID: 33748352; PMCID: PMC7972965
- Cohen RB, Hahn GV, Tabas J, Peeper J, Levitz CL, Sando A, Sando N, Zasloff M, Kaplan FS. The natural history of heterotopic ossification in patients who have fibrodysplasia ossificans progressiva. **J Bone Joint Surg Am** 75: 215-219, 1993
- Kaplan FS, Glaser DL, Shore EM, Deirmengian GK, Gupta R, Delai P, Morhart P, Smith R, Le Merrer M, Rogers JG, Connor JM, Kitterman JA. The phenotype of fibrodysplasia ossificans progressiva. **Clin Rev Bone Miner Metab** 3: 183-188, 2005

- Kaplan FS, Zasloff MA, Kitterman JA, Shore EM, Hong CC, Rocke DM. Early mortality and cardiorespiratory failure in patients with fibrodysplasia ossificans progressiva. **J Bone Joint Surg Am** 92: 686-691, 2010.
- Kaplan FS, Al Mukaddam M, Pignolo RJ. A cumulative analogue joint involvement scale for fibrodysplasia ossificans progressiva (FOP). **Bone** 101: 123-128, 2018a
- Kaplan FS, Al Mukaddam M, Pignolo RJ. Longitudinal patient-reported mobility assessment in fibrodysplasia ossificans progressiva (FOP). **Bone** 109:150-161, 2018b
- Kaplan FS, Al Mukaddam M, Pignolo RJ. Compartment syndrome of the thigh in a patient with fibrodysplasia ossificans progressiva. **J Orthopaedic Case Reports** 10(3): 103-107, 2020
- Kitterman JA, Kantanie S, Rocke DM, Kaplan FS. Iatrogenic harm caused by diagnostic errors in fibrodysplasia ossificans progressiva. **Pediatrics** 116: 654-661, 2005
- Pignolo RJ, Baujat G, Brown MA, De Cunto C, Di Rocco M, Hsiao EC, Keen R, Al Mukaddam M, Sang KLQ, Wilson A, White B, Grogan DR, Kaplan FS. Natural history of fibrodysplasia ossificans progressiva: cross-sectional analysis of annotated baseline phenotypes. **Orphanet J Rare Dis.** 2019 May 3;14(1):98. doi: 10.1186/s13023-019-1068-7
- Pignolo RJ, Bedford-Gay C, Liljestrom M, Durbin-Johnson BP, Shore EM, Rocke DM, Kaplan FS. The natural history of flare-ups in fibrodysplasia ossificans progressiva: a comprehensive global assessment. **J Bone Miner Res** 31:650-656, 2016
- Pignolo RJ, Durbin-Johnson BP, Rocke DM, Kaplan FS. Joint -specific risk of impaired function in fibrodysplasia ossificans progressiva (FOP). **Bone** 109:124-133, 2018
- Pignolo RJ, Cheung K, Kile S, Fitzpatrick MA, De Cunto C, Al Mukaddam M, Hsiao EC, Baujat G, Delai P, Eekhoff EMW, Di Rocco M, Grunwald Z, Haga N, Keen R, Levi B, Morhart R, Scott C, Sherman A, Zhang K, Kaplan FS. Self-reported baseline phenotypes from the international fibrodysplasia ossificans progressiva (FOP) association global registry. **Bone.** 2020 May;134:115274. doi: 10.1016/j.bone.2020.115274. Epub 2020 Feb 13
- Rocke DM, Zasloff M, Peeper J, Cohen RB, Kaplan FS. Age and joint-specific risk of initial heterotopic ossification in patients who have fibrodysplasia ossificans progressiva. **Clin Orthop** 301: 243-248, 1994
- Towler OW, Shore EM, Kaplan FS. Skeletal malformations and developmental arthropathy in individuals who have fibrodysplasia ossificans progressiva. **Bone.** 2020 Jan;130:115116. doi: 10.1016/j.bone.2019.115116. Epub 2019 Oct 23
- Towler OW, Kaplan FS, Shore EM. The developmental phenotype of the great toe in fibrodysplasia ossificans progressiva. **Front Cell Dev Biol.** 2020 Dec 8;8:612853. doi: 10.3389/fcell.2020.612853. eCollection 2020. **Front Cell Dev Biol.** 2020. PMID: 33364240
- Towler OW, Peck SH, Kaplan FS, Shore EM. Dysregulated BMP signaling through ACVR1 impairs digit joint development in fibrodysplasia ossificans progressiva (FOP). **Dev Biol.** 2020 Nov 17;470:136-146. doi: 10.1016/j.ydbio.2020.11.004. **Dev Biol.** 2021 January; 470: 136-146. PMID: 33217406

Zaghloul KA, Heuer GG, Guttenberg MD, Shore EM, Kaplan FS, Storm PB. Lumbar puncture and surgical intervention in a child with undiagnosed fibrodysplasia ossificans progressiva. *J Neursurg Pediatrics* 1: 91-94, 2008

3. Other Skeletal Anomalies of FOP

While malformations of the great toes are characteristic of FOP, other developmental anomalies are frequently observed. The culpable gene for FOP, ACVR1, has a clear effect on the induction of extra-skeletal bone formation. However, this BMP pathway receptor is expressed widely throughout skeletal development and has a seminal role in axial and appendicular chondrogenesis, prompting suspicion of widespread bone and joint defects in those with ACVR1 mutations (Towler et al., 2020).

There is widespread evidence for developmental arthropathy throughout the axial and appendicular skeleton at all ages in individuals with FOP. Asymmetric narrowing and subchondral sclerosis are present throughout the joints of the normotopic skeleton and osteophytes are common in the hips and knees of individuals who have FOP in all age groups. The costovertebral joints, intervertebral facet joints, and proximal tibio-fibular joints frequently show partial or total intra-articular ankylosis, particularly after age 13. The hips of FOP subjects are frequently malformed and dysplastic. There is also evidence of degenerative joint phenotypes after age 13, particularly in the spine, sacroiliac joints, and lower limbs (Towler et al., 2020).

Thus, the effects of ACVR1 mutation on the normotopic skeletons of individuals who have FOP extend beyond malformation of the great toes and include both morphological defects and developmental arthropathy. Associated degenerative joint disease occurring at multiple sites starts in adolescence and progresses throughout life. These phenotypes appear to be uncoupled from heterotopic bone formation, indicating a potential role for ACVR1 in the development and progression of degenerative joint disease (Towler et al., 2020).

Thus, FOP is a disease of not only progressive heterotopic ossification, but also widespread and extensive developmental arthropathy and associated degenerative joint disease. These findings have relevance for understanding the natural history of FOP and for designing and evaluating clinical trials with emerging therapeutics (Towler et al., 2020; Kaplan et al., 2020; Pignolo et al., 2020).

Stiffness of the neck is an early finding in most patients and can precede the appearance of HO at that site. Characteristic anomalies of the cervical spine include large posterior elements, tall narrow vertebral bodies, and variable fusion of the facet joints between C2 and C7 (Schaffer et al., 2005). Although the cervical spine often becomes ankylosed early in life, any minimal residual movement may eventually result in chronic headaches and painful arthritic symptoms.

Other skeletal anomalies associated with FOP include short malformed thumbs, clinodactyly, malformation of the temporomandibular joints, variable and often asymmetric fusions of the costovertebral and costotransverse joints, short broad femoral necks, and osteochondromas, most notably of the proximal medial tibias and femurs, but variably present throughout the normotopic skeleton (Deirmengian et al., 2008; Kaplan et al., 2009; Bauer et al., 2018; Kaplan et al., 2018; Towler et al., 2020). A common face signature is often noted (Hammond et al., 2012).

In summary, multiple skeletal abnormalities and joint malformations are often seen in individuals with FOP, and the following plain radiographs can aid in rapid phenotypic screening and clinical diagnosis:

- Anterior-Posterior (AP) of hands
- AP of both feet
- Lateral of cervical spine
- AP & lateral of chest
- AP of pelvis
- AP & lateral of both knees

References

Bauer AH, Bonham J, Gutierrez L, Hsiao EC, Motamedi D. Fibrodysplasia ossificans progressiva: a current review of imaging findings. **Skeletal Radiol** 47:1043-1050, 2018

Deirmengian GK, Hebel NM, O'Connell M, Glaser DL, Shore EM, Kaplan FS. Proximal tibial osteochondromas in patients with fibrodysplasia ossificans progressiva. **J Bone Joint Surg Am** 90: 366-374, 2008

Hammond P, Suttie M, Hennekam RC, Allanson J, Shore EM, Kaplan FS, The face signature of fibrodysplasia ossificans progressiva. **Am J Med Genet** 158A: 1368-1380, 2012

Kaplan FS, Xu M, Seemann P, Connor M, Glaser DL, Carroll L, Delai, P, Fastnact-Urban E, Forman SJ, Gillessen-Kaesbach G, Hoover-Fong J, Köster B, Morhart R, Pauli RM, Reardon W, Zaidi SA, Zasloff M, Mundlos S, Groppe J, Shore EM. Classical and atypical FOP phenotypes are caused by mutations in the BMP type I receptor ACVR1. **Human Mutation** 30: 379-390, 2009

Kaplan FS, Al Mukaddam M, Pignolo RJ. Acute unilateral hip pain in fibrodysplasia ossificans progressiva. **Bone** 109:115-119, 2018

Kaplan FS, Al Mukaddam M, Stanley A, Towler OW, Shore EM. Fibrodysplasia ossificans progressiva: a disorder of osteochondrogenesis. **Bone**. 2020 Jul;140:115539.doi:10.1016/j.bone.2020.115539.Epub 2020 Jul 27

Pignolo RJ, Wang H, Kapan FS. Fibrodysplasia ossificans progressiva (FOP): A segmental progeroid syndrome. **Front Endocrinol (Lausanne)**. 2020 Jan 10;10:908. doi: 10.3389/fendo.2019.00908. eCollection 2019

Schaffer AA, Kaplan FS, Tracy MR, O'Brien ML, Dormans JP, Shore EM, Harland RM, Kusumi K. Developmental anomalies of the cervical spine in patients with fibrodysplasia ossificans progressiva are distinctly different from those in patients with Klippel-Feil syndrome. **Spine** 30: 1379-1385, 2005

Towler OW, Shore EM, Kaplan FS. Skeletal malformations and developmental arthropathy in individuals who have fibrodysplasia ossificans progressiva. **Bone**. 2020 Jan;130:115116. doi: 10.1016/j.bone.2019.115116. Epub 2019 Oct 23.

4. Radiographic Features of FOP

Radiographic evaluation of heterotopic bone in FOP shows normal modeling and remodeling (Kaplan et al., 1994). Individuals with FOP are at increased risk of fractures of both the normotopic and heterotopic skeleton due to the increased risk of falls, immobility and prednisone use (Pignolo et al., 2016). Fractures

appear to heal normally in FOP. Bone scans are abnormal before HO can be detected by conventional radiographs (Kaplan et al., 1994; Mahboubi et al., 2001). Computed tomography, magnetic resonance imaging and ¹⁸F-NaF Positron Emission Tomography (PET) scans of early lesions have been described (Eekhoff et al., 2018; Botman et al., 2019; Botman et al., 2020). While these evaluation methods are generally superfluous from a diagnostic standpoint, they can provide a useful research perspective of the disease process and are being incorporated into evaluation schemes in contemporary clinical trials with various quantitative assessments (Rajapakse et al., 2017; Al Mukaddam et al., 2018; Eekhoff et al., 2018). The clinical diagnosis of FOP can be made by simple clinical evaluation that associates rapidly appearing soft tissue lesions with malformations of the great toes.

References

- Al Mukaddam M, Rajapakse CS, Pignolo RJ, Kaplan FS, Smith SE. Imaging assessment in fibrodysplasia ossificans progressiva: Qualitative, quantitative and questionable. **Bone** 109:147-152, 2018
- Botman E, Raijmakers PGHM, Yaqub M, Teunissen B, Netelenbos C, Lubbers W, Schwarte LA, Micha D, Bravenboer N, Schoenmaker T, de Vries TJ, Pals G, Smit JM, Koolwijk P, Trotter DG, Lammertsma AA, Eekhoff EMW. Evolution of heterotopic bone in fibrodysplasia ossificans progressiva: An [(18)F]NaF PET/CT study. **Bone** 124:1-6, 2019
- Botman E, Teunissen BP, Raijmakers P, de Graaf P, Yaqub M, Treurniet S, Schoenmaker T, Bravenboer N, Micha D, Pals G, Bökenkamp A, Netelenbos JC, Lammertsma AA, Eekhoff EM. Diagnostic value of magnetic resonance imaging in fibrodysplasia ossificans progressiva. **JBMR Plus**. 2020 Apr 28;4(6):e10363. doi: 10.1002/jbm4.10363. eCollection 2020 Jun
- Eekhoff EMW, Botman E, Coen Netelenbos J, de Graaf P, Bravenboer N, Micha D, Pals G, de Vries TJ, Schoenmaker T, Hoebink M, Lammertsma AA, Raijmakers PGHM. [18F]NaF PET/CT scan as an early marker of heterotopic ossification in fibrodysplasia ossificans progressiva. **Bone** 109:143-146, 2018
- Kaplan FS, Strear CM, Zasloff MA. Radiographic and scintigraphic features of modeling and remodeling in the heterotopic skeleton of patients who have fibrodysplasia ossificans progressiva. **Clin Orthop** 304: 238-247, 1994
- Mahboubi S, Glaser DL, Shore EM, Kaplan FS. Fibrodysplasia ossificans progressiva. **Pediatr Radiol** 31: 307-314, 2001
- Pignolo RJ, Bedford-Gay C, Liljethrom M, Durbin-Johnson BP, Shore EM, Rocke DM, Kaplan FS. The natural history of flare-ups in fibrodysplasia ossificans progressiva: a comprehensive global assessment. **J Bone Miner Res** 31:650-656, 2016
- Rajapakse CS, Lindborg C, Wang H, Newman BT, Kobe EA, Chang G, Shore EM, Kaplan FS, Pignolo RJ. Analog method for radiographic assessment of heterotopic bone in fibrodysplasia ossificans progressiva. **Acad Radiol** 24:321-327, 2017

5. Pathology of FOP Lesions

Early pre-osseous FOP lesions consist of an intense aggregation of mononuclear inflammatory cells including lymphocytes, macrophages, and mast cells in the perivascular spaces of edematous muscle (Gannon et al., 1998; Gannon et al., 2001). Mast cells, macrophages and cellular hypoxia play a direct role

in the generation of FOP lesions (Wang et al., 2016; Convente et al., 2018). Following the catabolic phase of muscle cell death, a highly anabolic fibroproliferative phase (often mistaken for *aggressive juvenile fibromatosis*) consists, in part, of Sca1+/PDGFR+/Tie2+/CD34- fibroadipogenic progenitor (FAP) cells that differentiate through an endochondral pathway into mature heterotopic bone (Kaplan et al., 1993; Lounev et al., 2009; Wosczyzna et al., 2012; Lees-Shepard et al., 2018).

References

- Convente MR, Chakkalakal SA, Yang E, Caron RJ, Zhang D, Kambayashi T, Kaplan FS, Shore EM. Depletion of Mast cells and macrophages impairs heterotopic ossification in an ACVR1 (R206H) mouse model of fibrodysplasia ossificans progressiva. **J Bone Miner Res** 33: 269-282, 2018
- Gannon FH, Glaser D, Caron R, Thompson LDR, Shore EM, Kaplan FS. Mast cell involvement in fibrodysplasia ossificans progressiva (FOP). **Hum Pathol** 32: 842-848, 2001
- Gannon FH, Valentine BA, Shore EM, Zasloff MA, Kaplan FS. Acute lymphocytic infiltration in an extremely early lesion of fibrodysplasia ossificans progressiva. **Clin Orthop** 346: 19-25, 1998
- Kaplan FS, Glaser DL, Shore EM, Pignolo RJ, Xu M, Zhang Y, Senitzer D, Forman SJ, Emerson SG, Hematopoietic stem cell contribution to ectopic skeletogenesis. **J Bone Joint Surg** 347-357, 2007
- Kaplan FS, Tabas J, Gannon FH, Finkel G, Hahn GV, Zasloff MA. The histopathology of fibrodysplasia ossificans progressiva: an endochondral process. **J Bone Joint Surg Am** 75-A: 220-230, 1993
- Lees-Shepard JB, Yamamoto M, Biswas AA, Stoessel SJ, Nicholas SE, Cogswell CA, Devarakonda PM, Schneider MJ Jr, Cummins SM, Legendre NP, Yamamoto S, Kaartinen V, Hunter JW, Goldhamer DJ. Activin-dependent signaling in fibro/adipogenic progenitors causes fibrodysplasia ossificans progressiva. **Nat Commun** 9(1):471. doi: 10.1038/s41467-018-02872-2, 2018
- Lounev VY, Ramachandran R, Wosczyzna MN, Yamamoto M, Maidment AD, Shore EM, Glaser DL, Goldhamer DJ, Kaplan FS. Identification of progenitor cells that contribute to heterotopic skeletogenesis. **J Bone Joint Surg Am** 91: 652-663, 2009
- Wang H, Lindborg C, Lounev V, Kim JH, McCarrick-Walmsley R, Xu M, Mangivani L, Groppe JC, Shore EM, Schipani E, Kaplan FS, Pignolo RJ. Cellular hypoxia promotes heterotopic ossification by amplifying BMP signaling. **J Bone Miner Res** 31:1652-1665, 2016
- Wosczyzna MN, Biswas AA, Cogswell CA, Goldhamer DJ. Multipotent progenitors resident in the skeletal muscle interstitium exhibit robust BMP-dependent osteogenic activity and mediate heterotopic ossification. **J Bone Miner Res** 27:1004-1017, 2012

6. Laboratory Findings in FOP

Routine biochemical studies are usually normal, although serum prostanoids, urinary basic fibroblast growth factor, cartilage-derived retinoic acid protein (CD-RAP), and alkaline phosphatase levels may be increased during the inflammatory, fibroproliferative, chondrogenic and osteogenic phases of flare-ups, respectively (Kaplan et al., 1998; Lindborg et al., 2018). Elevated numbers of circulating osteoprogenitor cells have been noted during early flare-ups. To date, no clinically reliable biomarkers have been identified.

References

Kaplan FS, Sawyer J, Connors S, Keough K, Shore E, Gannon F, Glaser D, Rocke D, Zasloff M, Folkman J. Urinary basic fibroblast growth factor: a biochemical marker for preosseous fibroproliferative lesions in patients with FOP. **Clin Orthop** 346: 59-65, 1998

Lindborg CM, Brennan TA, Wang H, Kaplan FS, Pignolo RJ. Cartilage-derived retinoic acid-sensitive protein (CD-RAP): A stage-specific biomarker of heterotopic endochondral bone ossification (HEO) in fibrodysplasia ossification progressiva (FOP). **Bone** 109:153-157, 2018

7. Etiology & Pathogenesis of FOP

Early observations in flies and vertebrates led to the hypothesis that the bone morphogenetic signaling pathway was dysregulated in FOP (Kaplan et al., 1990). In fact, the bone morphogenetic protein (BMP) signaling pathway is highly dysregulated in FOP. FOP cells over-express BMP4, cannot up-regulate expression of multiple BMP antagonists in response to a BMP challenge, and exhibit a defect in BMP receptor internalization with increased activation of downstream targets, suggesting that altered BMP receptor signaling participates in HEO formation in FOP (reviewed in Kaplan et al., 2009b).

Genome-wide linkage analysis localized the causative gene for FOP to chromosome 2q23-24, a locus containing the Activin A receptor, type 1 (ACVR1) gene encoding a BMP type 1 receptor. A recurrent heterozygous missense mutation (c.617G>A; p.R206H) in the glycine-serine (GS) activation domain of ACVR1 was identified in all affected individuals with classic features of either sporadic or inherited FOP, establishing mutation of this gene as the definitive cause of FOP and making molecular confirmation possible (Shore et al., 2006; Couzin, 2006; Kaplan et al., 2009a). A knock-in mouse model was used to confirm that this single nucleotide substitution is sufficient to induce all features associated with FOP (Chakkalakal et al., 2012).

Protein modeling predicted destabilization of the GS domain, consistent with enhanced activation of ACVR1 signaling as the underlying pathogenesis of the ectopic chondrogenesis, osteogenesis, and joint fusion of FOP (Shore et al., 2006; Groppe et al., 2007; Shen et al., 2009; van Dinther et al., 2010; Chaikaud et al., 2012; Culbert et al., 2014). The GS domain is a specific binding site for FKBP12, a highly conserved inhibitory protein that prevents leaky activation of type I receptors in the absence of ligand. ACVR1 (R206H) interacts less with FKBP12 in the absence of BMP, suggesting this impaired FKBP12-ACVR1 interaction contributes in part to BMP-independent pathway signaling (Shen et al., 2009; Groppe et al., 2011).

Basal and ligand-stimulated dysregulation of BMP pathway signaling characterize connective tissue progenitor cells from FOP patients, and *in vitro* and *in vivo* FOP models. ACVR1^{R206H} causes FOP through dysregulation of the BMP signaling pathway, in part, by receptor activation independently of ligands, but also by being hyper-responsive to BMP ligands as well as by responding to the normally antagonistic ligand Activin A (Billings et al., 2008; Shen et al., 2009; Culbert et al., 2014; Hatsell et al., 2015; Hino et al., 2015; Haupt et al., 2018; Wang et al., 2018; Allen et al., 2020). In addition, FOP ACVR1 signals in the absence of a normally required type I receptor partner, further demonstrating the loss of normal regulatory constraints on ACVR1 receptor activation (Allen et al., 2020). Additionally, early FOP lesions dramatically amplify BMP pathway signaling through an intracellular ligand-independent HIF-1 α mechanism thus establishing cellular hypoxia as a central mechanism for the stimulation and amplification of FOP lesions (Wang et al., 2016). Recent studies also show that the ACVR1^{R206H} FOP mutation alters mechanosensing and tissue stiffness during heterotopic ossification (Haupt et al., 2019; Stanley et al., 2019).

The development of joints in the mammalian skeleton depends on the precise regulation of multiple interacting signaling pathways including the bone morphogenetic protein (BMP) pathway, a key regulator of joint development, digit patterning, skeletal growth, and chondrogenesis. Recently, Towler and colleagues showed that the effects of increased Acvr1-mediated signaling by the Acvr1^{R206H} mutation are not limited to the first digit but alter BMP signaling, Growth Differentiation Factor-5 (Gdf5+) joint progenitor cell localization, and joint development in a manner that differently affects individual digits during embryogenesis. The Acvr1^{R206H} mutation leads to delayed and disrupted joint specification and cleavage in the digits and also alters the development of cartilage and endochondral ossification at sites of joint morphogenesis. These findings demonstrate an important role for ACVR1-mediated BMP signaling in the regulation of joint and skeletal formation, show a direct link between failure to restrict BMP signaling in the digit joint interzone and failure of joint cleavage at the presumptive interzone, and implicate ACVR1^{R206H} in impaired joint development (Towler, Peck, Kaplan, Shore, 2021).

References

- Allen, RS, Tager B, Shore EM, and Mullins MC. Fibrodysplasia ossificans progressiva mutant ACVR1 signals by multiple modalities in the developing zebrafish. **eLife**. 9:e53761, 2020. doi: <https://doi.org/10.7554/eLife.53761> PMID: 32897189
- Billings PC, Fiori JL, Bentwood JL, O'Connell MP, Jiao X, Nussbaum B, Caron RJ, Shore EM, Kaplan FS. Dysregulated BMP signaling and enhanced osteogenic differentiation of connective tissue progenitor cells from patients with fibrodysplasia ossificans progressiva (FOP). **J Bone Miner Res** 23:305-313, 2008
- Chaikuad A, Alfano I, Kerr G, Santivale CE, Boergermann JH, Triffitt JT, von Delft F, Knapp S, Knaus P, Bullock AN. Structure of the bone morphogenetic protein receptor ALK2 and implications for fibrodysplasia ossificans progressiva. **J Biol Chem** 287: 36990-36998, 2012
- Chakkalakal SA, Zhang D, Culbert AL, Convente MR, Caron RJ, Wright AC, Maidment AD, Kaplan FS, Shore EM. An Acvr1 Knock-in mouse has fibrodysplasia ossificans progressiva. **J Bone Miner Res** 27: 1746-1756, 2012
- Couzin J. Bone disease gene finally found. **Science** 312: 514-515, 2006
- Culbert AL, Chakkalakal SA, Theosmy EG, Brennan TA, Kaplan FS, Shore EM. Alk2 regulates early chondrogenic fate in fibrodysplasia ossificans progressiva heterotopic endochondral ossification. **Stem Cells** 32: 1289-1300, 2014
- Groppe JC, Shore EM, Kaplan FS. Functional modeling of the ACVR1 (R206H) mutation in FOP. **Clin Orthop Relat Res** 462: 87-92, 2007
- Groppe JC, Wu J, Shore EM, Kaplan FS. *In vitro* analysis of dysregulated R206H ALK2 kinase-FKBP12 interaction associated with heterotopic ossification in FOP. **Cells Tissues Organs** 194: 291-295, 2011
- Hatsell SJ, Idone V, Wolken DM, Huang L, Kim HJ, Wang L, Wen X, Nannuru KC, Jimenez J, Xie L, Das N, Makhoul G, Chernomorsky R, D'Ambrosio D, Corpina RA, Schoenherr CJ, Feeley K, Yu PB, Yancopoulos GD, Murphy AJ, Economides AN. ACVR1(R206H) receptor mutation causes fibrodysplasia ossificans progressiva by imparting responsiveness to activin A. **Sci Transl Med** 7(303)ra137, 2015
- Haupt J, Xu M, Shore EM. Variable signaling activity by FOP ACVR1 mutations. **Bone** 109:232-240, 2018

- Haupt J, Stanley A, McLeod CM, Cosgrove BD, Culbert AL, Wang L, Mourkioti F, Mauck RL, Shore EM. ACVR1^{R206H} FOP mutation alters mechanosensing and tissue stiffness during heterotopic ossification. **Mol Biol Cell** 30(1):17-29, 2019
- Hino K, Ikeya M, Horigome K, Matsumoto Y, Ebise H, Nishio M, Sekiguchi K, Shibata M, Nagata S, Matsuda S, Toguchida J. Neofunction of ACVR1 in fibrodysplasia ossificans progressiva. **Proc Natl Acad Sci USA** 112: 15438-15443, 2015Kaplan FS, Pignolo RJ, Shore EM. The FOP metamorphogene encodes a novel type I receptor that dysregulates BMP signaling. **Cytokine Growth Factor Rev** 20: 399-407, 2009b
- Kaplan FS, Tabas JA, Zasloff MA. Fibrodysplasia ossificans progressiva: A clue from the fly? **Calcif Tiss Int** 47: 117-125, 1990
- Kaplan FS, Xu M, Seemann P, Connor M, Glaser DL, Carroll L, Delai P, Fastnact-Urban E, Forman SJ, Gillessen-Kaesbach G, Hoover-Fong J, Köster B, Morhart R, Pauli RM, Reardon W, Zaidi SA, Zasloff M, Mundlos S, Groppe J, Shore EM. Classical and atypical FOP phenotypes are caused by mutations in the BMP type I receptor ACVR1. **Human Mutation** 30: 379-390, 2009a
- Shen Q, Little SC, Xu M, Haupt J, Ast C, Katagiri T, Mundlos S, Seemann P, Kaplan FS, Mullins MC, Shore EM. The fibrodysplasia ossificans progressiva R206H ACVR1 mutation activates BMP-independent chondrogenesis and zebrafish embargo ventralization. **J Clin Invest** 119: 3462-3472, 2009
- Shore EM, Xu M, Feldman GJ, Fenstermacher DA, Cho T-J, Choi IH, Connor JM, Delai P, Glaser DL, Le Merrer M, Morhart R, Rogers JG, Smith R, Triffitt JT, Urtizbera JA, Zasloff M, Brown MA, Kaplan FS. A recurrent mutation in the BMP type I receptor ACVR1 causes inherited and sporadic fibrodysplasia ossificans progressiva. **Nature Genetics** 38: 525-527, 2006
- Stanley A, Heo SJ, Mauck RL, Mourkioti F, Shore EM. Elevated BMP and Mechanical Signaling Through YAP1/RhoA Poises FOP Mesenchymal Progenitors for Osteogenesis. **J Bone Miner Res** 34(10):1894-1909, 2019
- Towler OW, Peck SH, Kaplan FS, Shore EM. Dysregulated BMP signaling through ACVR1 impairs digit joint development in fibrodysplasia ossificans progressiva (FOP). **Dev Biol.** 2021 Jan; 470:136-146. doi: 10.1016/j.ydbio.2020.11.004. PMID: 33217406
- van Dinther M, Visser N, de Gorter DJJ, Doorn J, Goumans M-J, de Boer J, ten Dijke P. ALK2 R206H mutation linked to fibrodysplasia ossificans progressiva confers constitutive activity to the BMP type I receptor and sensitizes mesenchymal cells to BMP-induced osteoblast differentiation and bone formation. **J Bone Miner Res** 25: 1208-1215, 2010
- Wang H, Lindborg C, Lounev V, Kim JH, McCarrick-Walmsley R, Xu M, Mangivani L, Groppe JC, Shore EM, Schipani E, Kaplan FS, Pignolo RJ. Cellular hypoxia promotes heterotopic ossification by amplifying BMP signaling. **J Bone Miner Res** 31:1652-1665, 2016
- Wang H, Shore EM, Pignolo RJ, Kaplan FS. Activin A amplifies dysregulated BMP signaling and induced chondro-osseous differentiation of primary connective tissue progenitor cells in patients with fibrodysplasia ossificans progressiva (FOP). **Bone** 109: 218-224, 2018

8. FOP Variants

All patients with classic clinical features of FOP (great toe malformations and progressive HO) have the same heterozygous mutation (c.617G>A; p.R206H) in the glycine-serine activation domain of ACVR1 (~97% of all FOP patients worldwide). Approximately 3% of FOP patients have been identified with clinical features unusual for FOP, most notably greater or lesser severity of the great toe malformations. These patients with variant clinical presentation of FOP have novel non-R206H activating mutations in the ACVR1 gene. Genotype-phenotype correlations have been observed between some ACVR1 mutations and the age of onset of HO or on embryonic skeletal development (Kaplan et al., 2009; Kaplan et al., 2015; reviewed in Huning & Gillessen-Kaesbach, 2014). A more detailed discussion of FOP variants is found in Section V.

References

Huning I & Gillessen-Kaesbach. Fibrodysplasia Ossificans Progressiva: Clinical Course, Genetic Mutations and Genotype-Phenotype Correlations. **Molec Syndromology** 5: 201-211, 2014

Kaplan FS, Kobori JA, Orellana C, Calvo I, Rosello M, Martinez F, Lopez B, Xu M, Pignolo RJ, Shore EM, Groppe JC. Multi-system involvement in a severe variant of fibrodysplasia ossificans progressiva (ACVR1c.772G>A; R258G): a report of two patients. **Am J Med Genetic A167A**:2265-2271, 2015

Kaplan FS, Xu M, Seemann P, Connor M, Glaser DL, Carroll L, Delai, P, Fastnact-Urban E, Forman SJ, Gillessen-Kaesbach G, Hoover-Fong J, Köster B, Morhart R, Pauli RM, Reardon W, Zaidi SA, Zasloff M, Mundlos S, Groppe J, Shore EM. Classical and atypical FOP phenotypes are caused by mutations in the BMP type I receptor ACVR1. **Human Mutation** 30: 379-390, 2009

9. The Immune System & FOP

In all affected individuals, FOP is caused by a heterozygous missense gain-of-function mutation in ACVR1. Loss of autoinhibition of the mutant receptor results in dysregulated BMP pathway signaling, and is necessary for the myriad developmental features of FOP, but may not be sufficient to induce the episodic flare-ups that lead to disabling post-natal HO and that are a hallmark of the disease. Evidence from all levels of investigation in humans and animal models strongly support that the innate immune system plays a key role in inducing episodes of HO.

Post-natal FOP flare-ups strongly implicate an underlying immunological trigger involving inflammation and the innate immune system (reviewed in Kaplan et al., 2016; Matsuo et al., 2019). Recent studies implicate mast cells, macrophages and hypoxia as well as canonical and non-canonical TGFβ/BMP family ligands in the amplification of mutant ACVR1 signaling leading to the formation of FOP lesions and resultant HO (Kaplan et al., 2016; Wang et al., 2016; Convente et al., 2018). BMP and Activin ligands that stimulate mutant ACVR1 signaling also have critical regulatory functions in the immune system (reviewed in Kaplan et al., 2016; Barruet et al., 2018). Cross-talk between the morphogenetic and immunological pathways that regulate tissue maintenance and repair identifies potential robust therapeutic targets for FOP (Wang et al., 2018).

References

Barruet E, Morales BM, Cain CJ, Ton AN, Wentworth KL, Chan TV, Moody TA, Haks MC, Ottenhoff TH, Hellman J, Nakamura MC, Hsiao EC. NF- κ B/MAPK activation underlies ACVR1-mediated inflammation in human heterotopic ossification. **JCI Insight**. 2018 Nov 15;3(22). pii: 122958. doi: 10.1172/jci.insight.122958. [Epub ahead of print]

Convente MR, Chakkalakal SA, Yang E, Caron RJ, Zhang D, Kambayashi T, Kaplan FS, Shore EM. Depletion of mast cells and macrophages impairs heterotopic ossification in an ACVR1 (R206H) mouse model of fibrodysplasia ossificans progressiva. **J Bone Miner Res** 33: 269-282, 2018

Kaplan FS, Pignolo RJ, Shore EM. Granting immunity to FOP and catching heterotopic ossification in the Act. **Semin Cell Dev Biol** 49: 30-36, 2016

Matsuo K, Chavez RD, Barruet E, Hsiao EC. Inflammation in fibrodysplasia ossificans progressiva and other forms of heterotopic ossification. **Curr Osteoporos Rep** 17(6):387-394, 2019

Wang H, Behrens EM, Pignolo RJ, Kaplan FS. ECSIT links TLR and BMP signaling in FOP connective tissue progenitor cells. **Bone** 109: 201-209, 2018

Wang H, Lindborg C, Lounev V, Kim JH, McCarrick-Walmsley R, Xu M, Mangivani L, Groppe JC, Shore EM, Schipani E, Kaplan FS, Pignolo RJ. Cellular hypoxia promotes heterotopic ossification by amplifying BMP signaling. **J Bone Miner Res** 31:1652-1665, 2016

10. Epidemiologic, Genetic & Environmental Factors in FOP

FOP is among the rarest of human afflictions, with an estimated incidence of 0.6-1.3 per million individuals (Connor & Evans, 1982; Baujat et al., 2017). All races are affected. There is no ethnic, racial, gender, or geographic predisposition. Autosomal dominant transmission with complete penetrance but variable expression is established. Inheritance can be from either mothers or fathers (Kaplan et al., 1993; Shore et al., 2005). Most cases arise as a result of a spontaneous new mutation (reviewed in Shore et al., 2005). A paternal age effect has been reported (Rogers & Chase, 1979). Maternal mosaicism may exist. Fewer than ten small families with multigenerational members with FOP are known worldwide. Phenotypic heterogeneity is observed (Shore et al., 2005).

Both genetic and environmental factors affect the phenotype of FOP. A study of three pairs of monozygotic twins with FOP found that within each pair, congenital toe malformations were identical. However, postnatal HO varied greatly depending on life history and environmental exposure to viral illnesses and to soft tissue trauma. Genetic factors appear to be the key determinants during prenatal development while environmental factors strongly influence postnatal progression of HO (Hebela et al., 2005).

References

Baujat G, Choquet R, Bouée S, et al. Prevalence of fibrodysplasia ossificans progressiva (FOP) in France: an estimate based on a record linkage of two national databases. **Orphanet J Rare Dis** 12(1):123, 2017 doi:10.1186/s13023-017-0674-5

Connor JM, Evans DA. Genetic aspects of fibrodysplasia ossificans progressiva. **J Med Genet** 19:35-39, 1982

Hebela N, Shore EM, Kaplan FS. Three pairs of monozygotic twins with fibrodysplasia ossificans progressiva: the role of environment in the progression of heterotopic ossification. **Clin Rev Bone Miner Metab** 3: 205-208, 2005

Kaplan FS, McCluskey W, Hahn G, Tabas J, Muenke M, Zasloff MA. Genetic transmission of fibrodysplasia ossificans progressiva. **J Bone Joint Surg Am** 75: 1214-1220, 1993

Rogers JG, Chase GA. Paternal age effect in fibrodysplasia ossificans progressiva. **J Med Genet** 16: 147-148, 1979

Shore EM, Feldman GJ, Xu M, Kaplan FS. The genetics of fibrodysplasia ossificans progressiva. **Clin Rev Bone Miner Metab** 3: 201-204, 2005

11. Genetic Testing & FOP

Definitive genetic testing of FOP by DNA sequence analysis can confirm a diagnosis of FOP prior to the appearance of HO (Kaplan et al., 2008). Clinical suspicion of FOP early in life on the basis of malformed great toes can lead to early clinical diagnosis, confirmatory diagnostic genetic testing (if appropriate), and the avoidance of harmful diagnostic and treatment procedures. Clinicians should be aware of the early diagnostic signs of FOP - congenital malformation of the great toes and episodic soft tissue swelling even before the appearance of HO. This awareness should prompt genetic consultation and testing and the institution of assiduous precautions to prevent injury and iatrogenic harm.

References

Kaplan FS, Xu M, Glaser DL, Collins F, Connor M, Kitterman J, Sillence D, Zackai E, Ravitsky V, Zasloff M, Ganguly A, Shore EM. Early diagnosis of fibrodysplasia ossificans progressiva. **Pediatrics** 121: e1295-e1300, 2008

12. Animal Models of FOP

Animal models of FOP are important in deciphering the pathophysiology of FOP and in testing possible therapies. Laboratory-generated animal models of FOP in *Drosophila*, zebrafish and mice with features of FOP have provided the opportunity to better understand the biology of BMP pathway-associated HO and to study the effectiveness and safety of currently available and emerging therapies (Kaplan et al., 1990; Shen et al., 2009; Chakkalakal et al., 2012; Kaplan et al., 2012; Le et al., 2012; LaBonty & Yellick, 2018; Le & Wharton, 2018; Mucha et al., 2018; LaBonty & Yellick, 2019; Allen et al., 2020). Mouse conditional knock-in models of the classic FOP mutation have been developed and are critical in establishing specificity of treatment for FOP as well as investigating many previously unexplored aspects of the condition (Hatsell et al., 2015; Chakkalakal et al., 2016; Lees-Shepard et al., 2018; Chakkalakal & Shore, 2019). Recently, FOP was confirmed clinically and genetically in two domestic shorthaired cats (Casal et al., 2019).

References

- Allen, RS, Tager B, Shore EM, and Mullins MC. Fibrodysplasia ossificans progressiva mutant ACVR1 signals by multiple modalities in the developing zebrafish. **eLife**. 9:e53761, 2020. doi: <https://doi.org/10.7554/eLife.53761> PMID: 32897189
- Casal ML, Engiles JB, Zakošek Pipan M, Berkowitz A, Porat-Mosenco Y, Mai W, Wurzburg K, Xu MQ, Allen R, ODonnell PA, Henthorn PS, Thompson K, Shore EM. Identification of the identical human mutation in ACVR1 in two cats with fibrodysplasia ossificans progressiva. **Vet Pathol** 56(4):614-618, 2019
- Chakkalakal SA, Shore EM. Heterotopic ossification in mouse models of fibrodysplasia ossificans progressiva. **Methods Mol Biol** 1891:247-255, 2019
- Chakkalakal SA, Uchibe K, Convente MR, Zhang D, Economides AN, Kaplan FS, Pacifici M, Iwamoto M, Shore EM. Palovarotene inhibits heterotopic ossification and maintains limb mobility and growth in mice with the human ACVR1 (R206H) fibrodysplasia ossificans progressiva (FOP) mutation. **J Bone Miner Res** 31:1666-1675, 2016
- Chakkalakal SA, Zhang D, Culbert AL, Convente MR, Caron RJ, Wright AC, Maidment AD, Kaplan FS, Shore EM. An Acvr1 Knock-in mouse has fibrodysplasia ossificans progressiva. **J Bone Miner Res** 27: 1746-1756, 2012
- Hatsell SJ, Idone V, Wolken DM, Huang L, Kim HJ, Wang L, Wen X, Nannuru KC, Jimenez J, Xie L, Das N, Makhoul G, Chernomorsky R, D'Ambrosio D, Corpina RA, Schoenherr CJ, Feeley K, Yu PB, Yancopoulos GD, Murphy AJ, Economides AN. ACVR1(R206H) receptor mutation causes fibrodysplasia ossificans progressiva by imparting responsiveness to activin A. **Sci Transl Med** 7(303)ra137, 2015
- Kaplan FS, Chakkalakal SA, Shore EM. Fibrodysplasia ossificans progressiva: mechanisms and models of skeletal metamorphosis. **Dis Model Mech** 5: 756-762, 2012
- Kaplan FS, Tabas JA, Zasloff MA. Fibrodysplasia ossificans progressiva: A clue from the fly? **Calcif Tiss Int** 47: 117-125, 1990
- LaBonty M, Yelick PC. Animal models of fibrodysplasia ossificans progressiva. **Dev Dyn** 247:279-288, 2018
- LaBonty M, Yelick PC. An adult zebrafish model of fibrodysplasia ossificans progressiva. **Methods Mol Biol** 1891:155-163, 2019
- Le VQ, Anderson E, Akiyama T, Wharton KA. Drosophila models of FOP provide mechanistic insight. **Bone** 109:192-200, 2018
- Le VQ, Wharton KA. Hyperactive BMP signaling induced by ALK2 (R206H) requires type II receptor function in a Drosophila model for classic fibrodysplasia ossificans progressiva. **Dev Dyn** 241:200-214, 2012
- Lees-Shepard JB, Yamamoto M, Biswas AA, Stoessel SJ, Nicholas SE, Cogswell CA, Devarakonda PM, Schneider MJ Jr, Cummins SM, Legendre NP, Yamamoto S, Kaartinen V, Hunter JW, Goldhamer DJ. Activin-dependent signaling in fibro/adipogenic progenitors causes fibrodysplasia ossificans progressiva. **Nat Commun** 9(1):471. doi: 10.1038/s41467-018-02872-2, 2018

Mucha BE, Hashiguchi M, Zinski J, Shore EM, Mullins MC. Variant BMP receptor mutations causing fibrodysplasia ossificans progressiva (FOP) in humans show BMP ligand-independent receptor activation in zebrafish. **Bone** 109:225-231, 2018

Shen Q, Little SC, Xu M, Haupt J, Ast C, Katagiri T, Mundlos S, Seemann P, Kaplan FS, Mullins MC, Shore EM. The fibrodysplasia ossificans progressiva R206H ACVR1 mutation activates BMP-independent chondrogenesis and zebrafish embargo ventralization. **J Clin Invest** 119: 3462-3472, 2009

13. Supportive Treatment in FOP

There is presently no definitive medical treatment for FOP. Management is currently supportive. High-dose glucocorticoids have limited use but are most effective in the management of the early inflammatory flare-ups affecting major joints of the appendicular skeleton and jaw, especially when used immediately after the onset of a flare-up. Oral and topical non-steroidal anti-inflammatory medications, cyclo-oxygenase-2 inhibitors, mast cell stabilizers, leukotriene inhibitors and occasional intravenous aminobisphosphonates are reported by patients to manage chronic pain, arthritic symptoms or ongoing disease progression (Kaplan et al., 2008; Pignolo et al., 2013).

Bone marrow transplantation is ineffective, as even a normal immune system has triggered FOP flare-ups in a genetically susceptible chimeric patient. Research to develop treatments for FOP has focused on targeted inhibition of the ACVR1 receptor, ACVR1 ligands, BMP pathway signaling, the pre-osseous chondrogenic anlagen of HO, and inflammatory triggers of disease activity, and offers hope for the future. Activation of the retinoid signaling pathway and retinoic acid receptor gamma (RAR γ) agonists inhibit chondrogenesis and HO and the RAR γ agonist Palovarotene is being studied in FDA-approved clinical trials for FOP. Additionally, a sponsored clinical trial using Anti-Activin A antibodies is underway (reviewed in Kaplan et al., 2017). Information about clinical trials on FOP can be found at: <http://www.clinicaltrials.gov/>

Removal of FOP HO is often followed by significant recurrence and expansion of HO. Surgical release of joint contractures is unsuccessful, and risks new trauma-induced HO. Spinal bracing is ineffective and surgical intervention is associated with numerous complications. Prophylactic dental approaches are essential. Dental therapy should preclude mandibular blocks and stretching of the jaw. Assiduous avoidance of intramuscular injections, muscle fatigue and passive movement of joints is essential. While physical therapy to maintain joint mobility may be harmful by provoking or exacerbating lesions, occupational therapy evaluations are often helpful. Prevention of falls, influenza, recurrent pulmonary infections and complications of restrictive chest wall disease is important (Kaplan et al., 2008; Pignolo et al., 2013).

References

Kaplan FS, LeMerrer M, Glaser DL, Pignolo RJ, Goldsby RE, Kitterman JA, Groppe J, Shore EM. Fibrodysplasia ossificans progressiva. **Best Pract Res Clin Rheumatol** 22: 191-205, 2008

Kaplan FS, Pignolo RJ, Al Mukaddam MM, Shore EM. Hard targets for a second skeleton: therapeutic horizons for fibrodysplasia ossificans progressiva (FOP). **Expert Opinion on Orphan Drugs** 5: 291-294, 2017

Pignolo RJ, Shore EM, Kaplan FS. Fibrodysplasia ossificans progressiva: diagnosis, management, and therapeutic horizons. In *Emerging Concepts in Pediatric Bone Disease*. **Pediatric Endocrinology Reviews**. 10(S-2): 437-448, 2013

14. Prognosis of FOP

Despite widespread HO and severe disability, some patients live productive lives into their seventh decade. Most, however, succumb earlier from cardiopulmonary complications of severe restrictive chest wall involvement (Kaplan, 2006; Kaplan, 2013).

Recently, tools to construct a conceptual framework for the clinical staging of FOP have been proposed. These staging measures for FOP assess the influence of HO and accelerated joint dysfunction (due to congenital abnormalities) on the ability to perform common functional activities, and thus a delay or lack of progression of functional loss from one stage to the next represents the ultimate test of efficacy for drug trials. This framework will serve both as a prediction tool for FOP progression as well as a critical opportunity to substantiate therapeutic interventions. Ultimately, this clinical staging will aid the field in moving toward earlier intervention at a stage when disease-modifying therapies may be most efficacious (reviewed in Pignolo & Kaplan, 2018).

Over the past decade, FOP research has identified robust genetic, molecular and cellular targets for therapy. Clinical trials are underway and more are set to occur. There is hope for the future.

References

Kaplan FS. The key to the closet is the key to the kingdom: a common lesson of rare diseases. **Orphan Disease Update** 24(3): 1-9, 2006

Kaplan FS. The skeleton in the closet. **Gene** 528: 7-11, 2013

Pignolo RJ, Kaplan FS. Clinical staging of fibrodysplasia ossificans progressiva. **Bone** 109: 111-114, 2018

15. Challenges of Therapeutic Assessment in FOP

Flare-ups of FOP are sporadic and unpredictable, and there is great individual variability in the rate of disease progression. Several large studies on the natural history of FOP have confirmed that it is impossible to predict the occurrence, duration or severity of an FOP flare-up, although characteristic anatomic patterning has been described. The rarity of FOP and the unpredictable nature of the condition make it extremely difficult to assess any therapeutic intervention, a fact recognized as early as 1918 by Julius Rosenstirn (Rosenstirn, 1918):

“The disease was attacked with all sorts of remedies and alternatives for faulty metabolism; every one of them with more or less marked success observed solely by its original author but pronounced a complete failure by every other follower. In many cases, the symptoms of the disease disappear often spontaneously, so the therapeutic effect (of any treatment) should not be unreservedly endorsed.”

These words ring true today as they did when they were written a century ago. Presently, there is no proven effective prevention or treatment for FOP. With the discovery of the FOP gene and emerging understanding of the pathology and molecular genetics of FOP, new pharmacologic strategies are emerging to definitively treat FOP. Presently, physicians are faced with an increasing number of potential medical interventions. Presently, clinical experience using these medications for FOP is mostly anecdotal (Kaplan et al., 2017).

In the next section of this report, we will review the major classes of medications that are being used to manage symptoms in patients who have FOP. We will provide a perspective on indications and contraindications for the use of such medications until more specific disease-modifying medication and therapies are available.

References

Kaplan FS, Pignolo RJ, Al Mukaddam MM, Shore EM. Hard targets for a second skeleton: therapeutic horizons for fibrodysplasia ossificans progressiva (FOP). **Expert Opinion on Orphan Drugs** 5: 291-294, 2017

Rosenstirn J. A contribution to the study of myositis ossificans progressiva. **Ann Surg** 68: 485-520, 591-637, 1918

IV. THE PATHOLOGIC AND PATHOPHYSIOLOGIC-BASED TREATMENT OF FOP

We emphasize that this report reflects the authors' experience and opinions on the various classes of symptom-modifying medications, and is meant only as a guide to this controversial area of therapeutics. Although there are common physical features shared by every person who has FOP, there are differences among individuals that may alter the potential benefits or risks of any medication or class of medications discussed here. The decision to use or withhold a particular medication must ultimately rest with an individual patient and his or her physician.

1. Introduction

The ultimate treatment of FOP will likely be based on integrated knowledge of the cellular and molecular pathophysiology of the condition. An abbreviated outline of our current knowledge is presented in Figure 1. Several recent reviews of treatment in FOP provide general background references (Kaplan et al., 2008; Pignolo et al., 2013; Kaplan et al., 2017) but interested clinicians are guided to this text for the most recent review of symptomatic treatment.

References

Kaplan FS, LeMerrer M, Glaser DL, Pignolo RJ, Goldsby RE, Kitterman JA, Groppe J, Shore EM. Fibrodysplasia ossificans progressiva. **Best Pract Res Clin Rheumatol** 22: 191-205, 2008

Kaplan FS, Pignolo RJ, Al Mukaddam MM, Shore EM. Hard targets for a second skeleton: therapeutic horizons for fibrodysplasia ossificans progressiva (FOP). **Expert Opinion on Orphan Drugs** 5: 291-294, 2017

Pignolo RJ, Shore EM, Kaplan FS. Fibrodysplasia ossificans progressiva: diagnosis, management, and therapeutic horizons. In *Emerging Concepts in Pediatric Bone Disease*. **Pediatric Endocrinology Reviews** 10 (S-2): 437-448, 2013

2. Corticosteroids in FOP

The rational use of corticosteroids early in the course of an FOP flare-up is based primarily on its potent anti-inflammatory effects (Rhen & Cidlowski, 2005; Hapgood et al., 2016) and on emerging knowledge of the importance of inflammatory triggers in FOP flare-ups (Kaplan et al., 2005; Kaplan et al., 2007; Yu et al., 2008; Kaplan et al., 2016).

Widespread favorable anecdotal reports from the FOP community suggest that a brief 4-day course of high-dose corticosteroids, begun within the first 24 hours of a flare-up, may help reduce the intense inflammation and tissue edema seen in the early stages of the disease. In a global assessment of FOP flare-ups involving more than 500 individuals, 198 treatments were reported. Anti-inflammatory agents were the most

common. Seventy-five percent used short-term glucocorticoids as a symptomatic treatment for flare-ups at appendicular sites. Fifty-five percent reported that glucocorticoids improved symptoms occasionally whereas 31% reported that they always did. Only 12% reported complete resolution of a flare-up with glucocorticoids. Forty-three percent reported rebound symptoms within 1 to 7 days after completing a course of glucocorticoids (Pignolo et al., 2016). The process of heterotopic ossification (HO) in FOP develops in stages. The very early stage is characterized by intense inflammatory infiltrates (Shore & Kaplan, 2010). Corticosteroids suppress inflammation by multiple mechanisms (Cruz-Topete & Cidlowski, 2015). How long this stage lasts, and the duration of corticosteroid use still needs to be elucidated.

The use of corticosteroids should be restricted to:

1. The extremely early symptomatic treatment of flare-ups that affect:
 - Major joints (e.g. hip)
 - The jaw
 - The submandibular area
2. The prevention of flare-ups following major soft tissue injury (severe trauma)
3. The prevention of flare-ups in emergent, elective, major or minor surgeries such as dental surgery, hypospadias repair, appendectomies, etc. (peri-operative use) as they may decrease the likelihood of HO.

Corticosteroids should not generally be used for the symptomatic treatment of flare-ups involving the neck or trunk due to the long duration and recurring nature of these flare-ups, and the difficulty in assessing the true onset of such flare-ups. On rare occasions, a brief course of corticosteroids may be used to break the cycle of recurrent flare-ups often seen in early childhood. However, the utility of this approach is not widely accepted, as flare-ups tend to recur rapidly following cessation of corticosteroid therapy.

Corticosteroids are most effective if used within the first 24 hours of a new flare-up that affects the movement of a major joint, prophylactically following major soft tissue trauma, or peri-operatively as noted above. The dose of corticosteroids is dependent upon body weight.

A typical dose of prednisone for acute flare-ups is 2 mg/kg/day (up to 100 mg), administered as a single daily dose for no more than 4 days (Table 1). In order to have the least suppressive effect on the hypothalamic-pituitary-adrenal axis, the medication should be given in the morning. However, some patients may tolerate the medication better if given as twice per day dosing. Equivalent doses of other steroids can also be used.

Alternatively, high dose intravenous corticosteroid pulse therapy may be considered, but must be performed with an inpatient hospitalization to monitor for potentially dangerous side-effects of hypertension (Sinha & Bagga, 2008; Table 1).

When prednisone is discontinued, a non-steroidal anti-inflammatory medication or COX-2 inhibitor (in conjunction with a leukotriene inhibitor) may be used symptomatically for the duration of the flare-up (Table 1). Corticosteroids should not be used for the long-term chronic treatment of FOP as chronic dependence due to adrenal suppression and other steroid-associated side-effects such as osteoporosis and iatrogenic Cushing's disease will likely result.

Corticosteroids are an important component in the management of a submandibular flare-up of FOP. Submandibular swelling in patients who have FOP can be a medical emergency and requires intensive precautionary measures to avoid catastrophic clinical deterioration. These measures include early identification of the submandibular flare-up, avoidance of lesional manipulation, airway monitoring, aspiration precautions, nutritional support due to the difficulty in swallowing, and the use of corticosteroids. The potentially dangerous nature of flare-ups in the submandibular region and jaw may dictate a slightly longer use of corticosteroids with an appropriate taper for the duration of the flare-up or until the acute swelling subsides (Janoff et al., 1996).

Flare-ups often result from over-use and soft tissue injuries. Prednisone – 1-2 mgs/kg, (per oral) once daily for 3-4 days is often used in attempt to prevent flare-up after severe soft-tissue injury. Do not use after minor bumps or bruises. Use prednisone prophylactically as directed for dental or surgical procedures.

While patients are encouraged to contact their physician at the earliest sign of a flare-up or following major trauma, many find it comforting to have a supply of prednisone on hand at home in case of an emergency. This “pill in the pocket” approach has been feasible and safe with a monitored reduction in emergency room and hospital visits.

References

Cruz-Topete D, Cidlowski JA. One hormone two actions: anti and pro-inflammatory effects of glucocorticoids. **Neuroimmunomodulation** 22: 20-32, 2015

Hapgood JP, Avenat C, Moliki JM. Glucocorticoid-independent modulation of GF activity: Implications for immunotherapy. **Pharmacol Ther** 165: 93-113, 2016

Janoff HB, Zasloff MA, Kaplan FS. Submandibular swelling in patients with fibrodysplasia ossificans progressiva. **Otolaryngol Head Neck Surg** 114: 599-604, 1996

Kaplan FS, Glaser DL, Shore EM, Pignolo RJ, Xu M, Zhang Y, Senitzer D, Forman SJ, Emerson SG. Hematopoietic stem-cell contribution to ectopic skeletogenesis. **J Bone Joint Surg Am** 89: 347-357, 2007

Kaplan FS, Pignolo RJ, Shore EM. Granting immunity to FOP and catching heterotopic ossification in the Act. **Semin Cell Dev Biol** 49: 30-36, 2016

Kaplan FS, Shore EM, Gupta R, Billings PC, Glaser DL, Pignolo RJ, Graf D, Kamoun M. Immunological features of fibrodysplasia ossificans progressiva and the dysregulated BMP4 Pathway. **Clin Rev Bone & Miner Metab** 3: 189-193, 2005

Pignolo RJ, Bedford-Gay C, Liljestrom M, Durbin-Johnson BP, Shore EM, Rocke DM, Kaplan FS. The natural history of flare-ups in fibrodysplasia ossificans progressiva: a comprehensive global assessment. **J Bone Miner Res** 31:650-656, 2016

Rhen T & Cidlowski JA. Anti-inflammatory action of glucocorticoids – new mechanisms for old drugs. **N Engl J Med** 353: 1711-1723, 2005

Shore EM, Kaplan FS. Inherited human diseases of heterotopic bone formation. **Nat Rev Rheumatol** 6: 518-527, 2010

Sinha A, Bagga A. Pulse steroid therapy. **Indian J Pediatrics** 75:1057-1066, 2008

van Staa TP, Cooper C, Leufkens HGM, Bishop N. Children and the risk of fractures caused by oral corticosteroids. **J Bone Miner Res** 18: 913-918, 2003

Yu PB, Deng DY, Lai CS, Hong CC, Cuny GD, Boussein ML, Hong DW, McManus PM, Katagiri T, Sachidanandan C, Nobuhiro K, Fukuda T, Mishina Y, Peterson RT, Bloch KD. BMP type I receptor inhibition reduces heterotopic ossification. **Nat Med** 14: 1363-1369, 2008

3. Cyclo-Oxygenase-2 (COX-2) Inhibitors & NSAIDs in FOP

Selective cyclo-oxygenase-2 (COX-2) inhibitors and non-steroidal anti-inflammatory medications (NSAIDs) may have a role in the management of FOP symptoms.

The body produces two types of prostaglandins: “physiological” prostaglandins and “inflammatory” prostaglandins. Physiological prostaglandins are normally produced in many of the body’s tissues and serve to protect organs, such as the stomach, from metabolic injury. Inflammatory prostaglandins are produced in response to injury, and play a major role in the inflammatory response to tissue injury and repair. Traditional NSAIDs such as aspirin, ibuprofen and indomethacin inhibit the formation of both physiological and inflammatory prostaglandins. The selective cyclo-oxygenase-2 (COX-2) inhibitors primarily inhibit inflammatory prostaglandins and leave most, but not all, of the physiological prostaglandins relatively intact (Katori & Majima, 2000; Van Ryn & Pairet, 2000).

Inflammatory prostaglandins are potent co-stimulatory molecules along with BMPs in the induction of normotopic and heterotopic bone (Weinreb et al. 1997; Jones et al. 1999; Convente et al., 2015) and are elevated in the urine of patients who have FOP, especially during times of disease flare-up (Levitz et al., 1992). These observations suggest that lowering baseline levels of inflammatory prostaglandins in patients with FOP may raise the threshold for HO even in the presence of promiscuously active ACVR1.

Studies in the orthopaedic literature have shown that lowering inflammatory prostaglandin levels in experimental animals dramatically raise the threshold for HO, thus, making it more difficult for heterotopic bone to form (DiCesare et al. 1991). Preoperative and postoperative treatment with NSAIDs in patients undergoing hip arthroplasty prevents HO (Brunnerkreef et al., 2013; Joice et al., 2018).

Compared to the parent class of NSAIDs, the selective COX-2 inhibitors offer the possibility of a lower gastrointestinal risk profile. Also, the half-life of most COX-2 inhibitors is conducive to a once or twice daily dosage regimen, a factor which may help promote patient compliance (Deeks et al. 2002).

However, substantial concerns have been raised about the safety of the COX-2 inhibitors in patients at high risk of cardiovascular and cerebrovascular disease (White et al. 2002; White et al. 2003; Grosser et al. 2017). Although COX-2 activity is necessary for the synthesis of inflammatory prostaglandins, it also controls the synthesis of prostacyclin, a prostaglandin that is essential for the health and patency of blood vessels, especially in the heart and brain.

While concerns have been raised about all COX-2 inhibitors (Fitzgerald, 2004; Topol, 2004), selective cox-2 inhibitors remain a rational choice for patients at low cardiovascular risk who have had serious gastrointestinal events or in patients who are at high risk of serious gastrointestinal events, such as

those with FOP who may need to use glucocorticoids intermittently for the treatment of acute flare-ups.

At the present time, the COX-2 inhibitor celecoxib (Celebrex), as well as etoricoxib (Arcoxia) is available in many countries and exhibits reduced gastrointestinal risk compared with other NSAIDs (Feng et al. 2018). Presently, safety and pharmacokinetic data are available for celecoxib in the pediatric population (Stempak et al., 2002). This medication is being used in patients with juvenile idiopathic arthritis. The results of a multicenter pharmacovigilance study in the US, showed a good safety profile of celecoxib compared to nonselective NSAIDs at a minimum 12-month follow-up (Sobel et al. 2014).

Studies on the NSAIDs and selective COX-2 inhibitors integrate important findings from the FOP laboratory on prostaglandin production, mast cell recruitment, and angiogenic factor release with the pathologic findings of severe inflammatory pre-osseous lesions of FOP. As with any condition, the relative risks and benefits of potential therapies must be weighed against the potential risks of the underlying condition being treated (Hochberg, 2003).

With all of the controversy swirling around the selective COX-2 inhibitors, the standard NSAIDs, which inhibit both COX-1 and COX-2 non-selectively, remain an option to consider in the symptomatic management of children and adults with FOP (Table 1). As with the chronic use of all NSAIDs, the risks of serious gastrointestinal side-effects, especially gastrointestinal bleeding, are possible, and special precautions may be warranted in susceptible individuals.

Finally, although there is no evidence that chronic treatment with COX-2 inhibitors or NSAIDs prevent flare-ups in FOP, COX-2 inhibitors or oral/topical NSAIDs may be helpful for symptomatic management of flare-ups and chronic arthropathy when corticosteroids are not indicated.

References

- Brunnekreef J, Hoogervorst P, Ploegmakers MJ, Rijnen WH, Schreurs BW. Is etoricoxib effective in preventing heterotopic ossification after primary total hip arthroplasty? **International Orthopaedics (SICOT)** 37:583-587, 2013
- Convente MR, Wang H, Pignolo RJ, Kaplan FS, Shore EM. The immunological contribution to heterotopic ossification disorders. **Curr Osteoporos Rep** 13:116-124, 2015
- Deeks JJ, Smith LA, Bradley MD. Efficacy, tolerability, and upper gastrointestinal safety of celecoxib for treatment of osteoarthritis and rheumatoid arthritis: systematic review of randomized controlled trials. **British Med J** (Review) 325(7365): 619, 2002
- DiCesare PE, Nimni ME, Pen L, Yazdi M, Cheung DT. Effects of indomethacin on demineralized bone-induced heterotopic ossification in the rat. **J Orthop Res** 9: 855-861, 1999
- Feng X, Tian M, Zhang W, Mei H. Gastrointestinal safety of etoricoxib in osteoarthritis and rheumatoid arthritis: A meta-analysis. **PLoS ONE** 2018; 13(1): e0190798
- Fitzgerald GA. Coxibs and cardiovascular disease. **N Engl J Med** 351: 1709-1711, 2004
- Grosser T, Ricciotti E, Fitzgerald GA. The cardiovascular pharmacology of non-steroidal anti-inflammatory drugs. **Trends Pharmacol Sci** 38:733-748, 2017

Hochberg Mc. COX-2: where are we in 2003? Be strong and resolute: continue to use COX-2 selective inhibitors at recommended dosages in appropriate patients. **Arthritis Res Ther** 5:28-31, 2003

Joice M, Vasileiadis GI, Amanatullah DF. Non-steroidal anti-inflammatory drugs for heterotopic ossification prophylaxis after total hip arthroplasty. **Bone Joint J** 100-B: 915-922, 2018

Jones, MK, Wang H, Peskar BM, Levin E, Itani RM Sarfeh IJ, Tarnawski AS. Inhibition of angiogenesis by nonsteroidal anti-inflammatory drugs: insight into mechanisms and implications for cancer growth and ulcer healing. **Nature Med** 5: 1418-1423, 1999

Katori M, Majima M. Cyclooxygenase-2: its rich diversity of roles and possible application of its selective inhibitors. **Inflammation Res** 49: 367-392, 2000

Levitz CL, Cohen RB, Zasloff MA, Kaplan FS. The role of prostaglandins in bone formation. Abstracts from The First International Symposium on Fibrodysplasia Ossificans Progressiva, September 25-26, 1991, Philadelphia, Pennsylvania. **Calcif Tissue Int** 50: 385-388, 1992

Sobel RE, Lovell DJ, Brunner HI, Weiss JE, Morris PW, et al. for the Pediatric Rheumatology Collaborative Study Group. Safety of celecoxib and nonselective nonsteroidal anti-inflammatory drugs in juvenile idiopathic arthritis: results of the phase 4 registry. **Pediatric Rheumatol Online J** 12: 29, 2014

Stempak D, Gammon J, Klein J, Koren G, Baruchel S. Single-dose and steady-state pharmacokinetics of celecoxib in children. **Clin Pharmacol Ther** 72: 490-497, 2002

Topol EJ. Failing the public health – rofecoxib, Merck, and the FDA. **N Engl J Med** 351:1707-1709, 2004

Van Ryn J, Pairet M: Clinical experience with cyclooxygenase-2 inhibitors. **Inflammation Res** 48: 247-254, 1999

Weinreb M, Suponitsky I, Keila S. Systemic administration of an anabolic dose of PGE₂ in young rats increases the osteogenic capacity of bone marrow. **Bone** 120: 521-526, 1997

White WB, Faich G, Borer JS, Makuch RW. Cardiovascular thrombotic events in arthritis trials of the cyclooxygenase-2 inhibitor celecoxib. **Am J Cardiol** 92: 411-418, 2003

White WB, Faich G, Whelton A, Maurath C, Ridge NJ, Verburg KM, Geis GS, Lefkowitz JB. Comparison of thromboembolic events in patients treated with celecoxib, a cyclooxygenase-2 specific inhibitor, versus ibuprofen or diclofenac. **Am J Cardiol** 89: 425-430, 2002

4. Topical Analgesics in FOP

Potential advantages of topical non-steroidal Anti-inflammatory Agents (NSAIDs) include lower initial rates of systemic absorption, reduced systemic adverse effects (including gastrointestinal toxicity) and directed application to area(s) of pain (Asbill et al., 2014; Branvold & Carvalho, 2014). Several topical agents, available as a gel, spray, or cream, are available for the treatment of musculoskeletal pain. In one study comparing three available topical applications, ketoprofen gel (2.5% w/w), was better than piroxicam gel (0.5% w/w), and slightly better than diclofenac gel (1% w/w) in the treatment of acute soft tissue injury that included a global assessment of treatment response, improvements in stiffness, restriction of mobility,

and pain on pressure and movement (Patel and Leswell, 1996). Ketoprofen gel also has a reported "cooling effect". In a head-to-head comparison study they were each applied three times daily. In clinical studies, topical NSAIDs are typically applied three times daily for acute pain.

In FOP, topical NSAIDs have anecdotally been used for both acute and chronic pain and applied 3-4 times daily. In the use of ketoprofen gel for FOP musculoskeletal complaints, a compounded formulation of 5% gel is commonly the initial dose, with the potential for upward titration to 15-20%.

Other topical agents include lidocaine patch or gel (both 5%). Topical lidocaine is most appropriate for patients with well localized neuropathic pain. Capsaicin cream, an alkaloid derived from chili peppers and thought to deplete substance P from primary afferent (sensory) neurons may have a theoretical advantage for pain control in FOP; however, clinical experience is very limited and concern over paradoxical effects mandates its very cautious use.

References

Asbill S, Sweitzer SM, Spigener S, Romero-Sandoval A. Compounded pain formulations: what is the evidence? **Intl J Pharmaceutical Compounding** 18: 278-286, 2014

Branvold A & Carvalho M. Pain management therapy: the benefits of compounded transdermal pain medication. **J Gen Practice** 2:1-8, 2014

Patel RK, Leswell PF. Comparison of ketoprofen, piroxicam, and diclofenac gels in the treatment of acute soft-tissue injury in general practice. General Practice Study Group. **Clin Ther** 18:497-507, 1996

5. Mast Cell Inhibitors in FOP

Among the most typical features of FOP flare-ups are the intense muscle edema, fibroproliferation, and angiogenesis characteristic of early pre-osseous FOP lesions, and the rapid spread of the lesions into adjacent tissue. A lesion may appear within hours and can reach an alarming size literally overnight. The sudden appearance and rapid spread of an FOP lesion suggests involvement of a repertoire of inflammatory mediators along with an abnormal connective tissue wound response, and points to a potential role for inflammatory mast cells and their mediators in the extension of the disease process.

Mast cells are indigenous cells in the body's connective tissues and arise from the bone marrow. They circulate in the blood as committed, but not terminally differentiated cells, and migrate into numerous tissues including skeletal muscle where they mature and reside as harmless bystanders until provoked by a traumatic or inflammatory stimulus. Mast cells are found in close proximity to blood vessels and nerves. In normal skeletal muscle, mast cells are sparsely distributed in the connective tissues between the muscle bundles. Mast cells contain granules of potent stored chemicals that induce edema, fibroproliferation and angiogenesis when released into the surrounding tissue. For many years, the role of mast cells was unknown, but it now appears that they play an important role in tissue repair and wound healing (Kaplan, 2002).

When mast cell recruitment and activation go awry, the process can lead to severe inflammatory reactions. This has long been recognized with mast cell activation in the skin and lungs, resulting in the symptoms of hives and asthma, respectively. However, very little is known about mast cells in the deeper tissues of the body such as the skeletal muscles. Mast cells are not easily visible

microscopically unless special stains are used to detect them. Mast cells are stimulated by a myriad of external and internal stimuli such as internal immune responses and external tissue injury.

Mast cells contain granules whose sequestered contents include histamine, heparin, angiogenic proteins, and matrix degrading enzymes that allow injured tissue to repair itself. Potent angiogenic proteins released by mast cells include basic fibroblast growth factor, vascular endothelial growth factor, and transforming growth factor beta. Mast cells also release a litany of inflammation-causing molecules including tumor necrosis factor alpha, prostaglandins, and leukotrienes. Upon release from the mast cells, these substances influence a vast array of biological processes including inflammation, immune function, angiogenesis, fibrous tissue formation, extracellular tissue remodeling, and tissue repair (Kaplan, 2002).

The intense inflammatory muscle edema, fibroproliferation, and angiogenesis characteristic of early pre-osseous FOP lesions and the rapid spread of these lesions along muscle planes into adjacent tissue suggested a potential role for mast cells in the FOP process. As little is known about the resident mast cells in skeletal muscle, a comprehensive analysis was undertaken of mast cell distribution in normal skeletal muscle, in uninvolved FOP muscle, in FOP lesions, in inflammatory and genetic muscle diseases, and in experimentally-induced animal models of HO (Gannon et al., 2001; Convente et al., 2018).

The findings of this study were startling and unexpected. Mobilization and activation of inflammatory mast cells was found at all stages of FOP lesional development. These data documented an important role for mast cells in the pathology of FOP lesions (Gannon et al., 2001).

The following hypothesis was developed based on observations and experimental data in the mast cell study:

Tissue injury in FOP patients leads to macrophage, mast cell, and lymphocyte migration into normally appearing skeletal muscle. Mediators released by mast cells stimulate a cycle of inflammatory edema, fibrosis, and angiogenesis which is potentiated at the leading edge of an advancing FOP lesion. Reactive fibroblasts within the muscle tissue produce proteins which lead to further proliferation of mast cells and a self-sustaining escalation of the disease process known as a flare-up. Eventually, transforming growth factor beta, released by mast cells and connective tissue progenitor cells, limits the lymphocytic recruitment and migration and thus the size and extent of the expanding lesion, while endogenous over-activity of ACVR1/ALK2 in the core of the fibroproliferative lesion drives the lesion towards ossification through an endochondral pathway.

The observation of mast cell mobilization in FOP lesions provided a novel and previously unrecognized opportunity to evaluate anti-mast cell therapies in limiting the spread of FOP lesions. In a mouse model of FOP, posttraumatic FOP lesions were evaluated and the proinflammatory cytokine response of TNF α , IL-1 β , and IL-6 was found to be elevated and prolonged in murine FOP lesions and in murine FOP mast cells. Importantly, depletion of mast cells and macrophages significantly impaired injury-induced HO in FOP mice (Convente et al, 2018).

Mast cells, macrophages, lymphocytes, and their associated inflammatory-mediators may also be reduced with the use of mast cell stabilizers, long-acting non-sedating antihistamines, leukotriene inhibitors, non-steroidal anti-inflammatory medications, c-kit tyrosine kinase inhibitors, and cox-2 inhibitors. Mast cell membrane stabilizers may reduce the release of angiogenic and chemotactic factors, while anti-histamines and leukotriene inhibitors may reduce the downstream effects of

released mediators (Simmons, 2004). Using an injury-induced, constitutively-active transgenic mouse model of FOP mast cell inhibition by cromolyn resulted in a dramatic reduction of HO (Brennan et al, 2017). Cromolyn significantly decreases the total number of mast cells and specifically diminishes the number of degranulating and resting degranulated mast cells in pre-osseous FOP lesions.

The c-kit tyrosine kinase inhibitor imatinib has been shown to induce mast cell apoptosis and decrease HO in an Achilles tendon injury model of HO (Werner et al, 2013) as well as in an injury-induced, constitutively-active transgenic mouse model of FOP (Wang et al, 2016). Imatinib has been successfully used to reduce airway hyper-responsiveness and mast cell number in severe asthma (Cahill et al., 2017) and to mitigate severe and unrelenting flare-ups in FOP (Kaplan et al, 2018). The optimal use of these medications and their potential long-term efficacy in FOP is presently unknown.

References

Brennan TA, Lindborg CM, Bergbauer CR, Wang H, Kaplan FS, Pignolo RJ. Mast cell inhibition as a therapeutic approach in fibrodysplasia ossificans progressiva (FOP). **Bone** 109: 259-266, 2017

Cahill KN, Katz HR, Cui J, Lai J, Kazani S, Crosby-Thompson A, Garofalo D, Castro M, Jarjour N, DiMango E, Erzurum S, Trevor JL, Shenoy K, Chinchilli VM, Wechsler ME, Laidlaw TM, Boyce JA, Israel E. KIT Inhibition by Imatinib in Patients with Severe Refractory Asthma. **N Engl J Med** 376: 1911-1920, 2017

Convente MR, Chakkalakal SA, Yang E, Caron RJ, Zhang D, Kambayashi T, Kaplan FS, Shore EM. Depletion of mast cells and macrophages impairs heterotopic ossification in an *Acvr1^{R206H}* mouse model of fibrodysplasia ossificans progressiva. **J Bone Miner Res** 33: 269-282, 2018

Gannon FH, Glaser D, Caron R, Thompson LDR, Shore EM, Kaplan FS. Mast cell involvement in fibrodysplasia ossificans progressiva. **Hum Pathol** 32: 842-848, 2001

Kaplan AP. Chronic urticaria and angioedema. **N Engl J Med** 346:175-179, 2002

Kaplan FS, Andolina JR, Adamson PC, Teachey DT, Finklestein JZ, Ebb DH, Whitehead B, Jacobs B, Siegel DM, Keen R, Hsiao E, Pignolo RJ. Early clinical observations on the use of imatinib mesylate in FOP: A report of seven cases. **Bone** 109: 276-280, 2018

Simmons FER. Advances in H₁ antihistamines. **N Engl J Med** 351: 2203-2217, 2004

Wang H, Lindborg C, Lounev V, Kim JH, McCarrick-Walmsley R, Xu M, Mangiavini L, Groppe JC, Shore EM, Schipani E, Kaplan FS, Pignolo RJ. Cellular hypoxia promotes heterotopic ossification by amplifying BMP signaling. **J Bone Miner Res** 31: 1652-65, 2016

Werner CM, Zimmermann SM, Wurgler-Hauri CC, et al. Use of imatinib in the prevention of heterotopic ossification. **HSSJ** 9: 166–170, 2013

6. Bisphosphonates in FOP

Bisphosphonates are a potent class of medications that have profound effects on bone remodeling and exert their primary effect by decreasing the life span of osteoclasts. Bisphosphonates are thus widely used in adults and children for the treatment of numerous bone diseases where bone resorption exceeds

bone formation - disorders such as steroid-induced osteoporosis, idiopathic osteoporosis, osteogenesis imperfecta, Paget's disease, fibrous dysplasia, and bone cancer (Orcel & Beaudreuil, 2002; Nogginuera et al., 2003; Chen & Sambrook, 2012; Baroncelli & Bertelloni, 2014).

In addition, bisphosphonates have been used experimentally and anecdotally in the symptomatic management of flare-ups in FOP. The first clinically used bisphosphonate, etidronate, when administered at high doses, potently inhibited mineralization of newly formed cartilage and bone protein and had been proposed as a possible treatment for FOP and other disorders of HO. Etidronate had been studied in FOP because of its inhibitory effect on bone mineralization and its potential to impair ossification at high dosages (Brantus & Meunier, 1998). Unfortunately, at high doses for long durations, etidronate caused osteomalacia (soft bones) and impaired ossification of the entire skeletal system, not just the heterotopic bone of the "second skeleton." Its utility is therefore limited.

Unlike etidronate, the newer aminobisphosphonates have no appreciable effect on inhibiting mineralization or causing osteomalacia. In 2005, Schuetz and colleagues reported generally beneficial anecdotal effects of high-dose aminobisphosphonates in preventing recurrence of HO in high-risk patients with established HO who were undergoing surgery to excise heterotopic bone. One of the five patients reported had FOP (Schuetz et al., 2005).

The newer aminobisphosphonates have been used anecdotally for many years as an adjunctive symptomatic treatment for refractory flare-ups in FOP. Over the past 15 years, many patients in the FOP community have used Pamidronate empirically for the symptomatic relief of refractory flare-ups, especially those that are prolonged or fail to respond to corticosteroids. Approximately three-quarters anecdotally report rapid improvement in the symptoms and signs of a flare-up while one-quarter report no improvement in the symptoms or signs of the flare-up (F. Kaplan, personal observation).

Importantly, there seems to be no protective effect on the occurrence of subsequent flare-ups in any of the patients treated with intravenous aminobisphosphonates. While these anecdotal patient reports are not scientifically valid, they constitute an important set of anecdotal observations that compel further stringent scientific inquiry in controlled clinical studies.

The bisphosphonate protocols used in the adjunctive, symptomatic treatment of FOP flare-ups have varied slightly between the patients (depending on age, body weight, and site of involvement) but in general were similar. The most commonly used protocol is summarized in Section V - Classes of Medications (Table 1).

In all patients, serum calcium was monitored prior to treatment to assure that it was in the normal range, as hypocalcemia is a contraindication to the use of intravenous Pamidronate or any of the aminobisphosphonates (Rosen & Brown, 2003). All patients had adequate daily oral calcium and vitamin D supplementation during and following treatment. A serum calcium, phosphate, albumin, alkaline phosphatase, 25-Hydroxy vitamin D, BUN, creatinine and complete blood count (CBC) should also be obtained at baseline.

Treatment schedules were based upon published guidelines for children and adolescents with osteogenesis imperfecta as that group constitutes the largest known group of children and adolescents in whom intravenous aminobisphosphonates have been used (Rauch et al., 2002; Falk et al., 2003; Rauch et al., 2003; DiMeglio & Peacock 2006). Although Zoledronate has been used, the potency and side-effects in young children are a concern and the more prolonged exposure to Pamidronate is preferred in FOP (George et al, 2015). The treatment of these children has allowed us to extrapolate protocols and safety data for FOP.

Patients between two and three years of age received Pamidronate at a dose of 0.75 mg/kg/day for three consecutive days by slow intravenous infusion over 4-5 hours each day. Patients over the age of three years received Pamidronate at a dose of 1.0 mg/kg/day for three days by slow intravenous infusion over 4-5 hours each day, with a maximal dose of 60 mgs daily. On the first day of the first cycle of treatment, the patient receives half the dose. Lower total doses of Pamidronate (½ listed dose on days 2 and 3) and substantially longer durations of infusions (8-10 hours) have been reported anecdotally and have been well-tolerated. The three-day cycle of treatment should be repeated only during refractory flare-ups and no more than 4 times annually. An alternate approach is to administer intravenous Pamidronate about one week apart, and assess the patient to see if there is a medical response in between. In many cases, it has been found that two doses are sufficient. Pamidronate should not be used routinely to treat flare-ups. It should be used primarily for the adjunctive treatment of flare-ups where other modes of symptomatic treatment have failed.

Pamidronate should be diluted in normal saline according to the following table (Guidelines courtesy of F.H. Glorieux: Shriners’ Hospital for Children, Montreal):

mg of Pamidronate	ml of Normal Saline	ml/hour
0-5	50	15
5.1-10	100	30
10.1-15	150	45
15.1-25	250	75
25.1-50	500	150
50.1-60	600	180

The maximal concentration of Pamidronate should be 0.1 mg/ml. The IV tubing should be flushed at the end of the infusion to ensure full dose delivery.

Side-effects of intravenous Pamidronate infusions in FOP patients included flu-like symptoms of fever, chills, and muscle aches. These symptoms can often be lessened by pre-treatment with acetaminophen. One patient developed tetany (uncontrolled muscle contractions due to a low vitamin D level in the blood prior to ameliorative therapy with Pamidronate), and one patient developed peripheral phlebitis (inflammation of the vein) at the intravenous infusion site, which required inpatient intravenous antibiotic treatment.

A published case report documents the development of iatrogenic osteopetrosis in a child treated with 60 mgs of intravenous Pamidronate every three weeks for two years. The child did not have FOP and the cumulative doses reported far exceeded any published recommendations for the use of Pamidronate in skeletal diseases (Whyte et al., 2003).

Several important rare but serious complications the bisphosphonates are necessary to note - osteonecrosis of the jaw (ONJ) and low-energy femoral fractures. The following references contain detailed reviews of these rare but serious complications (Bilezikian, 2006; Black et al., 2010; Khosla et al., 2007; Shane et al., 2010; Vargas-Franco et al., 2018).

Bisphosphonates have a long half-life and can reside in the skeleton for many years after the infusion. In women of child-bearing potential, the risk of bisphosphonate exposure on the fetus with future pregnancies is unknown.

A recent study showed that osteoclast inhibition does not affect HO enhanced by the FOP-related mutation (Kawao et al., 2016), so any effect of aminobisphosphonates on HO, if any, are not due to anti-osteoclastic activity, but through other less-explored mechanisms. Clearly, if the aminobisphosphonates are truly beneficial in the treatment of FOP flare-ups, there must be a mechanism of action that is very brief and substantially different from that of osteoclast inhibition from which the medication derives its beneficial effects in the normotopic skeleton.

One intriguing line of investigation concerns the role of inflammatory cells in triggering HO. Kan and colleagues showed that systemically delivered bisphosphonates powerfully and specifically inhibited monocytes and led to substantial inhibition of trauma-induced HO in a BMP4-transgenic mouse model of HO (Kan et al., 2009).

Intravenous aminobisphosphonates have also been shown to modulate macrophages and various lymphocyte subpopulations in the circulation and may be responsible for its dose-related side-effects of causing flu-like symptoms. We cannot yet rule-out the possibility that aminobisphosphonates may affect early lymphocytic and monocytic infiltration into skeletal muscle seen in both BMP4-induced FOP-like lesions and in FOP lesions themselves. It is also likely that the aminobisphosphonates directly inhibit the metabolic activity of monocytes and macrophages that play such key roles in the response of the innate immune system in FOP (Convente et al., 2018).

Several studies provide some additional clues. These studies document the potent antiangiogenic effects of the aminobisphosphonates by decreasing serum vascular endothelial growth factor (VEGF) levels and basic fibroblast growth factor (bFGF) levels in cancer patients with bone metastasis (Santini et al., 2002; Wood et al., 2002). Compelling evidence has emerged that aminobisphosphonates inhibit endothelial cell adhesion, migration and survival through suppression of multiple prenylation-dependent signaling pathways (Hasmim et al., 2007). Other independent studies have shown that aminobisphosphonates have potent anti-angiogenic properties by inhibiting endothelial cell differentiation (Yamada et al., 2009). Taken together, these data strongly suggest that the aminobisphosphonates may be potent anti-angiogenic agents.

Other possible mechanisms by which the aminobisphosphonates might affect FOP lesions include a direct inhibition on the proliferation of a rapidly dividing population of cells. Such an effect was noted in studies investigating the effects of aminobisphosphonates on cancer cells *in vitro* (Tassone et al., 2000; Green, 2003). It is possible that Pamidronate and Zoledronate may affect one or more cell types in an early FOP lesion. Another study showed (Idris et al., 2008) that aminobisphosphonates cause osteoblast apoptosis and inhibit bone nodule formation *in vitro*, thus suggesting that aminobisphosphonates may have a direct effect on inhibiting osteoblastic ability, especially in early bone nodules, as in FOP.

It remains unclear whether bisphosphonates have effects on flare-ups, though anecdotally they seem to decrease the flare symptoms in some patients. As with all medications, the risks and benefits need to be assessed carefully. Only rigorous controlled investigations *in vitro* and *in vivo*, as well as placebo-controlled clinical trials will be able to definitively decipher these possibilities and provide a solid rational basis for determining whether or not one or more of the aminobisphosphonates may have a beneficial role in the treatment of FOP.

Of course, intravenous aminobisphosphonates are indicated for the prevention and treatment of steroid-associated bone loss, a common problem in FOP patients (Nogginuera et al., 2003; Staa et al., 2003; Chen & Sambrook, 2012; Baroncelli & Bertelloni, 2014; Buckley & Humphrey, 2018).

Dentists should be made aware of any prior bisphosphonate use.

Of note, Denosumab, a monoclonal antibody to RANK ligand, is a potent anti-resorptive drug approved for the treatment of osteoporosis and certain cancers. As far as we are aware, the use of Denosumab has not been used in patients with FOP and is not recommended at this time.

References

- Baroncelli GI, Bertelloni S. The use of bisphosphonates in pediatrics. **Horm Res Paediatr** 82: 290-302, 2014
- Bilezikian JP. Osteonecrosis of the jaw – do bisphosphonates pose a risk? **N Engl J Med** 355: 2278-2281, 2006
- Black DM, Kelly MP, Genant HK, Palermo L, Eastell R, Bucci-Rechtweg, Cauley J, Leung PC, Boonen S, Santora A, de Papp A, Bauer DC. Bisphosphonates and fractures of the subtrochanteric or diaphyseal femur. **N Engl J Med** 362: 1761-1771, 2010
- Brantus JF, Meunier PJ. Effects of intravenous etidronate and oral corticosteroids in fibrodysplasia ossificans progressiva. **Clin Orthop** 346: 117-120, 1998
- Buckley L, Humphrey MB. Glucocorticoid-Induced Osteoporosis. **New Engl J Med** 379: 2547-2556, 2018
- Chen JS, Sambrook PN. Antiresorptive therapies for osteoporosis: a clinical overview. **Nat Rev Endocrinol** 8:81–91, 2012
- Convente MR, Chakkalakal SA, Yang E, Caron RJ, Zhang D, Kambayashi T, Kaplan FS, Shore EM. Depletion of Mast cells and macrophages impairs heterotopic ossification in an ACVR1 (R206H) mouse model of fibrodysplasia ossificans progressiva. **J Bone Miner Res** 33: 269-282, 2018
- DiMeglio LA, Peacock M. Two-year clinical trial of oral alendronate versus intravenous pamidronate in children with osteogenesis imperfecta. **J Bone Miner Res** 21: 132-140, 2006
- Falk MJ, Heeger S, Lynch KA, DeCaro KR, Bohach D, Gibson KS, Warman ML. Intravenous bisphosphonate therapy in children with osteogenesis imperfecta. **Pediatrics** 111: 573-578, 2003
- George S, Weber DR, Kaplan P, Hummel K, Monk HM, Levine MA. Short-term safety of zoledronic acid in young patients with bone disorders: an extensive institutional experience. **J Clin Endocrinol Metab** 100: 4163-4171, 2015
- Green JR. Antitumor effects of bisphosphonates. **Cancer** 97 (supplement): 840-847, 2003
- Hasmim M, Bieler G, Rüegg C. Zoledronate inhibits endothelial cell adhesion, migration and survival through the suppression of multiple, prenylation-dependent signaling pathways. **J Throm Haemost** 5: 166-173, 2007
- Idris AI, Rojas J, Greig IR, Van't Hof RJ, Ralston SH. Aminobisphosphonates cause osteoblast apoptosis and inhibit bone nodule formation in vitro. **Calcif Tissue Int** 82: 191-201, 2008

- Kan L, Liu Y, McGuire TL, Berger DM, Awatramani RB, Dymecki SM, Kessler JA. Dysregulation of local stem/progenitor cells as a common cellular mechanism for heterotopic ossification. **Stem Cells** 27: 150-156, 2009
- Kawao N, Yano M, Tamura Y, Okumoto K, Okada K, Kaji H. Role of osteoclasts in heterotopic ossification enhanced by fibrodysplasia ossificans progressiva-related activin-like kinase 2 mutation in mice. **J Bone Miner Metab** 34: 517-525, 2016
- Khosla S, Burr D, Cauley J, Dempster DW, Ebeling PR, Felsenberg D, Gagel RF, Gilsanz V, Guise T, Koka S, McCauley LK, McGowan J, McKee MD, Mohla S, Pendrys DG, Raisz LG, Ruggiero SL, Shafer DM, Shum L, Silverman SL, Van Poznak CH, Watts N, Woo SB, Shane E. Bisphosphonate-associated osteonecrosis of the jaw: report of a task force of The American Society for Bone and Mineral Research. **J Bone Miner Res** 22: 1479-1491, 2007
- Nogginuera A, Ros JB, Pavia C, Alcover E, Valls C, Villaronga M, Gonzalez E. Bisphosphonates, a new treatment for glucocorticoid-induced osteoporosis in children. **J Pediatr Endocrinol Metab** 16: 529-536, 2003
- Orcel P, Beaudreuil J. Bisphosphonates in bone disease other than osteoporosis. **Joint Bone Spine** 69: 19-27, 2002
- Rauch F, Plotkin H, Zeitlin L, Glorieux FH. Bone mass, size, and density in children and adolescents with osteogenesis imperfecta: effect of intravenous pamidronate therapy. **J Bone Miner Res** 18: 610-614, 2003
- Rauch F, Travers R, Plotkin H, Glorieux FH. The effects of intravenous pamidronate on the bone tissue of children and adolescents with osteogenesis imperfecta. **J Clin Invest** 110: 1293-1299, 2002
- Rosen CJ, Brown S. Severe hypocalcemia after intravenous bisphosphonate therapy in occult vitamin D deficiency. **N Engl J Med** 348: 1503-1504, 2003
- Santini D, Vincenzi B, Avvisati G, Dicuonzo G, Battistoni F, Gavasci M, Salerno A, Denaro V, Tonini G. Pamidronate induces modifications of circulating angiogenic factors in cancer patients. **Clin Cancer Res** 8: 1080-1084, 2002
- Schuetz P, Mueller B, Christ-Crain M, Dick W, Haas H. Amino-bisphosphonates in heterotopic ossification: first experience in five consecutive cases. **Spinal Cord** 43: 604-610, 2005
- Shane E. Evolving data about subtrochanteric fractures and bisphosphonates. **N Engl J Med** 362: 1825-1827, 2010
- Staa TPV, Cooper C, Leufkens HGM, Bishop N. Children and the risk of fractures caused by oral corticosteroids. **J Bone Miner Res** 18: 913-918, 2003
- Tassone P, Forciniti S, Galea E, Morrone G, Turco MC, Martinelli V, Tagliaferri P, Venuta S. Growth inhibition and synergistic induction of apoptosis by zoledronate and dexamethasone in human myeloma cell lines. **Leukemia** 14: 841-844, 2000
- Whyte MP, Wenkert D, Clements KL, McAlister WH, Mumm S. Bisphosphonate-induced osteopetrosis. **N Engl J Med** 349: 457-463, 2003

Wood J, Bonjean K, Ruetz S, Bellahcene A, Devy L, Foidart JM, Castronovo V, Green JR. Novel antiangiogenic effects of the bisphosphonate compound zoledronic acid. **J Pharmacol Exp Therap** 302: 1055-1061, 2002

Yamada J, Tsuno NH, Kitayama J, Tsuchiya T, Yoneyama S, Asakage M, Okaji Y, Nishikawa T, Tanaka J, Takahashi K, Nagawa H. Anti-angiogenic property of zoledronic acid by inhibition of endothelial progenitor cell differentiation. **J Surg Res** 151: 115-120, 2009

Vargas-Franco JW, Castaneda B, Rédiní F, Gómez DF, Heymann D, Lézot F. Paradoxical side effects of bisphosphonates on the skeleton: What do we know and what can we do? **J Cell Physiol** 233: 5696-5715, 2018

7. Imatinib in FOP

The often relentless flare-ups, ongoing discomfort and progressive loss of axial mobility of early childhood pose a special challenge in the symptomatic management of FOP. Presently, there are no adequate solutions for this problem. Research studies have identified multiple potential targets for therapy in FOP, and novel drug candidates are being developed for testing in clinical trials. A complementary approach seeks to identify approved drugs that could be re-purposed against defined targets in FOP.

One such drug is imatinib mesylate, a tyrosine kinase inhibitor originally developed for use in patients with chronic myeloid leukemia (CML). Imatinib has the desirable effect of attacking multiple targets involved in the early hypoxic and inflammatory stages of FOP flare-ups, including HIF1- α , PDGFR α , c-KIT, and multiple MAP kinases (Cahill et al., 2017; Galli, 2017). Notably, imatinib is effective in the treatment of systemic mast cell disease and inhibits multiple inflammatory proteins implicated in the formation of HO. Thus, imatinib has potential impact on major therapeutic targets of FOP.

Based on compelling biologic rationale, strong preclinical data, and a favorable safety profile, imatinib has been prescribed on an off-label basis in a non-trial setting in seven children with continuous FOP flare-ups, predominantly in the axial regions which were not responsive to standard-of-care regimens (Wang et al., 2016; Kaplan et al., 2018). All seven children failed to demonstrate any durable symptomatic response to the standard medications used to manage symptoms of FOP such as corticosteroids, non-steroidal anti-inflammatory agents, cromolyn or intravenous bisphosphonates.

All seven children were referred to a pediatric hematologist-oncologist or a pediatric rheumatologist for consideration of imatinib therapy after detailed consultation with the parents on the relative risks and benefits of off-label use of imatinib for FOP. Parents were informed that imatinib use was on an off-label basis and was not part of a clinical research study. The parents were also informed that progress would be monitored clinically, and that radiographs would not be performed routinely.

Anecdotal reports in these cases document that the medication was well-tolerated with an overall reported decrease in the intensity of flare-ups in the six children who took the medication. Moreover, the parents of all six children who were able to take imatinib on a daily basis noted subjective decreases in flare-up intensity after several weeks of use (Kaplan et al., 2018).

Clinical trials for rare diseases commonly focus on one target and one potential therapeutic at a time. However, the exigencies of clinical care in a real-world setting require flexibility in managing symptomatic disease, especially when no other alternatives are available. Approved medicines for one condition may have potential off-target effects for another and thereby be suitable for off-label use on a compassionate

basis. Early anecdotal experience with such medications may suggest useful parameters for monitoring meaningful endpoints in future clinical trials.

Presently, there is no definitive evidence that imatinib prevents or ameliorates flare-ups in FOP. However, early clinical observations support the implementation of clinical trials of imatinib in children with uncontrolled FOP flare-ups (Kaplan et al., 2018).

References

Cahill KN, Katz HR, Cui J, Lai J, Kazani S, Crosby-Thompson A, Garofalo D, Castro M, Jarjour N, DiMango E, Erzurum S, Trevor JL, Shenoy K, Chinchilli VM, Wechsler ME, Laidlaw TM, Boyce JA, Israel E. KIT Inhibition by Imatinib in Patients with Severe Refractory Asthma. **N Engl J Med** 376:1911-1920, 2017

Galli SJ. Mast Cells and KIT as Potential Therapeutic Targets in Severe Asthma. **N Engl J Med** 376:1983-1984, 2017

Kaplan FS, Andolina JR, Adamson PC, Teachey DT, Finklestein JZ, Ebb DH, Whitehead B, Jacobs B, Siegel DM, Keen R, Hsiao E, Pignolo RJ. Early clinical observations on the use of imatinib mesylate in FOP: A report of seven cases. **Bone** 109: 276-280, 2018

Wang H, Lindborg C, Lounev V, Kim JH, McCarrick-Walmsley R, Xu M, Mangivani L, Groppe JC, Shore EM, Schipani E, Kaplan FS, Pignolo RJ. Cellular hypoxia promotes heterotopic ossification by amplifying BMP signaling. **J Bone Miner Res** 31: 1652-1665, 2016

8. Muscle Relaxants in FOP

Early FOP flare-ups are associated with intense mast cell, macrophage, and lymphocytic infiltration into skeletal muscle and are often accompanied by intense inflammatory changes within regions of locally damaged or necrotic skeletal muscle. Areas of relatively healthy skeletal muscle bordering the lesion are thus subject to metabolic changes that would lead to muscle spasm and fiber shortening. The judicious short-term use of muscle relaxants such as cyclobenzaprine (Flexeril), metaxalone (Skelaxin), or baclofen (Liorisal) may help to decrease muscle spasm and maintain more functional activity even in the setting of an evolving FOP lesion (Glaser & Kaplan, 2005). This is especially true for painful flare-ups involving the limbs. The chronic use of muscle relaxants between episodes of flare-ups is not advised due to multiple drug interactions and central nervous system (depressant) effects. Careful attention to dosing schedules is important, as certain muscle relaxants (such as baclofen) need to be tapered slowly to avoid side-effects and others (such as cyclobenzaprine) can only be used for short periods of time up to 2-3 weeks.

References

Glaser DL, Kaplan FS. Treatment considerations for the management of fibrodysplasia ossificans progressiva. **Clin Rev Bone Miner Metab** 3: 243-250, 2005

9. Chemotherapy Agents & Radiation Therapy in FOP

The definitive diagnosis of FOP is often delayed due to the rarity of the condition and the failure to associate the tumor-like soft tissue swellings with the congenital malformations of the great toes. As a result, many children with FOP are misdiagnosed as having a wide range of benign or malignant conditions. It is not surprising, therefore, that many children with FOP have been treated with unnecessary chemotherapy, dangerous surgical excisions, and damaging radiotherapy before the definitive diagnosis of FOP has been made. It would be important to note retrospectively if radiation therapy or any of the chemotherapy agents had been helpful in altering the natural history of the condition. There has been no convincing anecdotal evidence that either radiation therapy or any of the standard chemotherapy agents such as actinomycin, adriamycin, cyclophosphamide, doxorubicin, ifosfamide, methotrexate, rituximab, TNF- α inhibitors, vinblastine, vincristine or any others were helpful for patients with FOP. In fact, many of these medications caused harmful long-term side-effects. The use of these approaches is, therefore, contraindicated in the treatment of FOP (Glaser & Kaplan, 2005; Kaplan et al., 2008).

References

Glaser DL, Kaplan FS. Treatment considerations for the management of fibrodysplasia ossificans progressiva. **Clin Rev Bone Miner Metab** 3: 243-250. 2005

Kaplan FS, Le Merrer M, Glaser DL, Pignolo RJ, Goldsby R, Kitterman JA, Groppe J, Shore EM. Fibrodysplasia ossificans progressiva (FOP). **Best Practice & Research – Clinical Rheumatology** 22: 191-205, 2008

10. Bone Marrow Transplantation in FOP

Bone marrow derived stem cells have been implicated in the ectopic bone formation of FOP (reviewed in Kaplan et al., 2007). The replacement of these stem cells by bone marrow transplantation has been suggested as a possible cure for FOP. However, the definitive contribution of bone marrow derived stem cells to the formation of heterotopic bone has remained obscure. Careful clinical observations were made of an FOP patient who underwent bone marrow transplantation twenty-five years earlier for the treatment of intercurrent aplastic anemia. Replacement of the FOP patient's bone marrow with normal donor bone marrow cured his fatal bone marrow condition but was not sufficient to prevent further HEO and progression of his FOP. However, acute immunoablation and chronic immunosuppression quenched the activity of his FOP (Kaplan et al., 2007).

In complementary transplantation studies in mice, blood cells derived from the bone marrow contributed to the early inflammatory and to the late marrow repopulating stages of BMP4-induced bone formation, but were not present in the fibroproliferative, chondrogenic or osteogenic stages of the FOP-like lesions (Kaplan et al., 2007).

Taken together, these findings demonstrated that bone marrow transplantation did not cure FOP in this patient, most likely because the hematopoietic cells from the bone marrow were not the source of cells that formed the FOP lesions. However, even normal bone marrow-derived cells were capable of stimulating HO in a genetically susceptible individual (Kaplan et al., 2007). Recent genetic experiments and bone marrow transplantation studies in FOP mouse models substantiate this finding (Chakkalakal et al., 2016; Dey et al., 2016), although a non-hematopoietically derived population of resident tissue macrophages remains a possible trigger.

These findings are of immense research interest and vital clinical importance, and they exemplify powerfully how much can be learned by careful observation in an individual patient. They also illustrate the importance of the immune system in triggering FOP flare-ups. At present, however, the general use of potent immunosuppressive medications is not advocated in the routine management of FOP, and would likely be extremely dangerous and possibly life-threatening if it were applied broadly to the FOP community. At the present time, (and until further studies are performed in appropriate animal models), this international consortium recommends against the use of chronic immunosuppressive medications in the management of FOP.

References

Chakkalakal SA, Uchibe K, Convente MR, Zhang D, Economides AN, Kaplan FS, Pacifici M, Iwamoto M, Shore EM. Palovarotene inhibits heterotopic ossification and maintains limb mobility and growth in mice with the human ACVR1 (R206H) fibrodysplasia ossificans progressiva (FOP) mutation. **J Bone Miner Res** 31:1666-1675, 2016

Dey D, Bagarova J, Hatsell SJ, Armstrong KA, Huang L, Ermann J, Vonner AJ, Shen Y, Mohedas AH, Lee A, Eekhoff EM, van Schie A, Demay MB, Keller C, Wagers AJ, Economides AN, Yu PB. Two tissue-resident progenitor lineages drive distinct phenotypes of heterotopic ossification. **Sci Transl Med** 2016 Nov 23;8(366):366ra163

Kaplan FS, Glaser DL, Shore EM, Pignolo RJ, Xu M, Zhang Y, Senitzer D, Forman SJ, Emerson SG. Hematopoietic stem-cell contribution to ectopic skeletogenesis. **J Bone Joint Surg Am** 89: 347-357, 2007

11. Miscellaneous Agents & Approaches in FOP

The chronic use of antiangiogenic agents, calcium binders, colchicine, fluoroquinolone antibiotics, mineralization inhibitors, PPAR-gamma agonists, TNF- α inhibitors and warfarin have been described anecdotally or reported with either unsatisfactory or equivocal results (Moore et al., 1986; Bocciardi & Ravazzolo R, 2010; Gatti et al., 2010; Kaplan et al., 2010). At the present time, the use of these medications or approaches cannot be endorsed.

Maxillofacial surgery has been reported in one patient with FOP and was beneficial for the patient from a quality of life standpoint despite recurrence of HO. There is 100% risk of recurrence of HO after jaw surgery which should be highly discouraged and remain a management choice of last resort (Eekhoff et al., 2017).

While there has been one case report of successful surgical excision of heterotopic bone in a patient with FOP, such an approach is not recommended, as the literature is littered with casualties following similar adventures (Benetos et al., 2006).

References

Benetos IS, Mavrogenis AF, Themistocleous GS, Kanellopoulos AD, Papagelopoulos PJ, Soucacos PN. Optimal treatment of fibrodysplasia ossificans progressiva with surgical excision of heterotopic bone, indomethacin, and irradiation. **J Surg Orthop Adv** 15: 99-104, 2006

Bocciardi R, Ravazzolo R. Is there a biological basis for treatment of fibrodysplasia ossificans progressiva with rosiglitazone? Potential benefits and undesired effects. **PPAR Res.** 2010;2010:541927. doi: 10.1155/2010/541927. Epub 2010 Jun 16.

Eekhoff EMW, Netelenbos JC, de Graaf P, Hoebink M, Bravenboer N, Micha D, Pals G, de Vries TJ, Lammertsma AA, Raijmakers PG, van Es RJ. Flare-Up After Maxillofacial Surgery in a Patient with Fibrodysplasia Ossificans Progressiva: An [18F]-NaF PET/CT Study and a Systematic Review. **JBMR Plus** 2:55-58, 2017

Gatti D, Viapiana O, Rossini M, Silvano A. Rosiglitazone therapy is associated with major clinical improvements in a patient with fibrodysplasia ossificans progressiva. **J Bone Miner Res** 25:1460-1462, 2010

Kaplan FS, Pignolo RJ, Shore EM. Viewing FOP through rosi-colored glasses. **J Bone Miner Res** 25: 2295-2296, 2010

Moore, SE, Jump A, Smiley JD. Effect of warfarin sodium therapy on excretion of 4-carboxy-L-glutamic acid in scleroderma, dermatomyositis, and myositis ossificans progressiva. **Arthritis Rheum** 29: 344-351, 1986

12. Definitive Therapeutic Targets in FOP

“With so much being discovered about how the BMPs act, it might be possible to develop drugs that would block some part of the BMP pathway and therefore prevent the progression of what is a horrible, nightmare disease.”

- Brigid Hogan (Roush, 1996)

The ultimate goal of FOP research is the development of treatments that will prevent, halt, or even reverse the progression of the condition. The prevention and treatment of HO in FOP, as in any of the more common forms of HO, will ultimately be based on at least one of four approaches: disrupting the inductive signaling pathways, suppressing the inflammatory triggers, altering the relevant osteoprogenitor cells in the target tissues, and/or modifying the tissue environment so that it is less conducive to heterotopic osteogenesis (Reviewed in Wentworth et al., 2019; Pignolo & Kaplan, 2020).

The identification of the recurrent heterozygous missense point mutation that causes FOP in all classically affected individuals provides a specific pharmaceutical target and a rational point of intervention in a critical signaling pathway. The discovery of the FOP gene identifies ACVR1 as a susceptible pharmaceutical target for the treatment of FOP (Shore et al., 2006). Plausible therapeutic strategies to inhibiting BMP signaling in FOP include inhibitory RNA technology (Kaplan et al., 2012), monoclonal antibodies directed against ACVR1 (Kaplan et al., 2017), small molecule selective signal transduction inhibitors (STIs) of ACVR1 (Hong et al., 2009; Kaplan et al., 2017; Williams et al., 2021), small molecule signal transduction inhibitors against inflammatory triggers and osteoprogenitor cells (Kaplan et al., 2018), retinoic acid receptor gamma (RAR γ) agonists (Shimono et al., 2011; Chakkalakal et al., 2016; Kaplan & Shore, 2011), anti-Activin A antibodies, (Hatsell et al., 2015; Hino et al., 2016; Kaplan et al., 2016; Vanhoutte et al., 2020) and inhibition of HIF1- α / mTOR signaling (Wang et al., 2016; Hino et al., 2017; Maekawa et al., 2020).

There has been substantial recent interest in clinical trials for novel and urgently-needed treatments for FOP. The International Clinical Council on FOP (ICC) was established in 2016 to provide

consolidated and coordinated advice on the best practices for clinical care and clinical research for individuals who suffer from FOP. The Clinical Trials Committee of the ICC developed a focused list of key considerations that encompass the specific and unique needs of the FOP community - considerations that are endorsed by the entire ICC. These considerations complement established protocols for developing and executing robust clinical trials by providing a foundation for helping to ensure the safety of subjects with FOP in clinical research trials (Hsiao et al., 2018). While there is risk, there is also much benefit and hope (Kaplan et al., 2020).

It is still too early to determine which one of these approaches or combinations of approaches will be most effective, and all are being studied intensively in preclinical and/or clinical studies (www.clinicaltrials.gov; https://www.ifopa.org/ongoing_clinical_trials_in_fop). Much of the present worldwide collaborative research effort in FOP is focused on this area of research, and detailed accounts of the work and progress can be found in the Twenty Eighth Annual Report of the FOP Collaborative Research Project (Kaplan, Al Mukaddam, Shore et al., 2020), as well as in recent reviews.

References

- Chakkalakal SA, Uchibe K, Convente MR, Zhang D, Economides AN, Kaplan FS, Pacifici M, Iwamoto M, Shore EM. Palovarotene inhibits heterotopic ossification and maintains limb mobility and growth in mice with the human ACVR1 (R206H) fibrodysplasia ossificans progressiva (FOP) mutation. **J Bone Miner Res** 31:1666-1675, 2016
- Hatsell SJ, Idone V, Wolken DM, Huang L, Kim HJ, Wang L, Wen X, Nannuru KC, Jimenez J, Xie L, Das N, Makhoul G, Chernomorsky R, D'Ambrosio D, Corpina RA, Schoenherr CJ, Feeley K, Yu PB, Yancopoulos GD, Murphy AJ, Economides AN. ACVR1(R206H) receptor mutation causes fibrodysplasia ossificans progressiva by imparting responsiveness to activin A. **Sci Transl Med.** 7(303)ra137, 2015
- Hino K, Horigome K, Nishio M, Komura S, Nagata S, Zhao C, Jin Y, Kawakami K, Yamada Y, Ohta A, Toguchida J, Ikeya M. Activin-A enhances mTOR signaling to promote aberrant chondrogenesis in fibrodysplasia ossificans progressiva. **J Clin Invest** 127: 3339-3352, 2017
- Hino K, Ikeya M, Horigome K, Matsumoto Y, Ebise H, Nishio M, Sekiguchi K, Shibata M, Nagata S, Matsuda S, Toguchida J. Neofunction of ACVR1 in fibrodysplasia ossificans progressiva. **Proc Natl Acad Sci USA** 112: 15438-15443, 2015
- Hong CC, Yu PB, Application of small molecules BMP inhibitors in physiology and disease. **Cytokines Growth Factor Rev** 20: 409-418, 2009
- Hsiao EC, Di Rocco M, Cali A, Zasloff M, Al Mukaddam M, Pignolo RJ, Grunwald Z, Netelenbos C, Keen R, Baujat G, Brown MA, Cho TJ, De Cunto C, Delai P, Haga N, Morhart R, Scott C, Zhang K, Diecidue RJ, Friedman CS, Kaplan FS, Eekhoff EMW. Special considerations for clinical trials in fibrodysplasia ossificans progressiva (FOP). **Br J Clin Pharmacol.** 2018 Oct 3. doi: 10.1111/bcp.13777 [Epub ahead of print]
- Kaplan FS, Al Mukaddam M, Shore EM. Twenty Seventh Annual Report of the fibrodysplasia ossificans progressiva (FOP) collaborative research project. **IFOPA Website** (www.ifopa.org). Fall, 2018

Kaplan FS, Al Mukaddam M, Baujat G, Cali A, Cho-T-J, DeCunto C, Delai P, Diecidue RJ DiRocco M, Friedman C, Grunwald Z, Haga N, Hsiao EC, Keen R, Morhart R, Netelenbos JC, Scott C, Zasloff MA, Zhang K, Eekhoff EMW, Pignolo RJ. Editorial - The twilight zone: benefit, risk & hope in clinical trials for FOP. **ICCFOP.org; IFOPA.org**. December 3, 2020

Kaplan FS, Andolina JR, Adamson PC, Teachey DT, Finklestein JZ, Ebb DH, Whitehead B, Jacobs B, Siegel DM, Keen R, Hsiao E, Pignolo RJ. Early clinical observations on the use of imatinib mesylate in FOP: A report of seven cases. **Bone** 109: 276-280, 2018

Kaplan J, Kaplan FS, Shore EM. Restoration of normal BMP signaling levels and osteogenic differentiation in FOP mesenchymal progenitor cells by mutant allele-specific targeting. **Gene Therapy** 19: 786-790, 2012

Kaplan FS, Pignolo RJ, Al Mukaddam MM, Shore EM. Hard targets for a second skeleton: therapeutic horizons for fibrodysplasia ossificans progressiva (FOP). **Expert Opinion on Orphan Drugs** 5: 291-294, 2017

Kaplan FS, Pignolo RJ, Shore EM. Granting immunity to FOP and catching heterotopic ossification in the Act. **Semin Cell Dev Biol** 49: 30-36, 2016

Kaplan FS, Shore EM. Derailing heterotopic ossification and RARing to go. **Nat Med** 17: 420-421, 2011

Maekawa H, Kawai S, Nishio M, Nagata S, Jin Y, Yoshitomi H, Matsuda S, Toguchida J. Prophylactic treatment of rapamycin ameliorates naturally developing and episode -induced heterotopic ossification in mice expressing human mutant ACVR1. **Orphanet J Rare Dis**. 2020 May 24;15(1):122. doi: 10.1186/s13023-020-01406-8.

Pignolo RJ, Kaplan FS. Druggable targets, clinical trial design and proposed pharmacological management in fibrodysplasia ossificans progressiva. **Expert Opinion on Orphan Drugs**. p. 1-9. <https://doi.org/10.1080/21678707.2020.1751122>

Shimono K, Tung W-e, Macolino C, Chi A, Didizian JH, Mundy C, Chandraratna RA, Mishina Y, Enomoto-Iwamoto M, Pacifici M, Iwamoto M. Potent inhibition of heterotopic ossification by nuclear retinoic acid receptor- γ agonists. **Nat Med** 17: 454-460, 2011

Shore EM, Xu M, Feldman GJ, Fenstermacher DA, Cho T-J, Choi IH, Connor JM, Delai P, Glaser DL, Le Merrer M, Morhart R, Rogers JG, Smith R, Triffitt JT, Urtizberea JA, Zasloff M, Brown MA, Kaplan FS. A recurrent mutation in the BMP type I receptor ACVR1 causes inherited and sporadic fibrodysplasia ossificans progressiva. **Nat Genetics** 38: 525-527, 2006

Vanhoutte F, Liang S, Ruddy M, Zhao A, Drewery T, Wang Y, DelGizzi R, Forleo-Neto E, Rajadhyaksha M, Herman G, Davis JD. Pharmacokinetics and pharmacodynamics of Garetosmab (Anti-Activin A): Results from a first-in-human phase 1 study. **J Clin Pharmacol**. 2020 Jun 18. doi: 10.1002/jcph.1638

Wang H, Lindborg C, Lounev V, Kim JH, McCarrick-Walmsley R, Xu M, Mangiavini L, Groppe JC, Shore EM, Schipani E, Kaplan FS, Pignolo RJ. Cellular Hypoxia Promotes Heterotopic Ossification by Amplifying BMP Signaling. **J Bone Miner Res** 31: 1652-65, 2016

Wentworth KL, Masharani U, Hsiao EC. Therapeutic advances for blocking heterotopic ossification in fibrodysplasia ossificans progressiva. **Br J Clin Pharmacol** 85(6):1180-1187, 2019

Williams EP, Bagarova J, Kerr G, Xia DD, Place ES, Dey D, Shen Y, Bocobo GA, Mohedas AH, Huang X, Sanderson PE, Lee A, Zheng W, Economides AN, Smith JC, Yu PB, Bullock AN. Saracatinib is an efficacious clinical candidate for fibrodysplasia ossificans progressiva. **JCI Insight**. 2021 Mar 11:95042. doi: 10.1172/jci.insight.95042. Epub ahead of print. PMID: 33705358

V. SPECIAL MEDICAL CONSIDERATIONS IN FOP

1. Introduction

Individuals who have FOP can also develop common problems (gall bladder disease, appendicitis, colds, earaches, etc.) as with anyone in the general population. Generally, the safest way to diagnose and treat these problems in a patient with FOP is to ask the question: “How would I evaluate this patient if he or she did not have FOP?” Following that, the “FOP filter” can be applied to ask: “Given the nature of the possible intercurrent medical problem, and the relative risks that particular problem presents in relation to FOP, are there any diagnostic or treatment procedures that should or should not be undertaken (or perhaps alternative diagnostic procedures might be more appropriate)?” Using that approach, diagnostic dilemmas can often be resolved and appropriate care delivered. When questions remain, experts on FOP should be consulted (Kaplan et al., 2018; see Section XII – Authors’ Contact Information).

In addition to common medical problems that individuals with FOP might have, there are a number of special medical considerations for FOP patients that are worthy of very special attention. They are presented below.

2. Injury Prevention in FOP

Prevention of soft-tissue injury and muscle damage remain a hallmark of FOP management. Intramuscular injections must be avoided. Routine childhood diphtheria-tetanus-pertussis immunizations administered by intramuscular injection pose a substantial risk of permanent heterotopic ossification (HO), as do arterial punctures whereas measles-mumps-rubella immunizations administered by subcutaneous injection and routine venipuncture pose little risk (Lanchoney et al., 1995). Biopsies of FOP lesions are never indicated and will likely cause additional HO.

Permanent ankylosis of the jaw may be precipitated by minimal soft tissue trauma during routine dental care. Assiduous precautions are necessary in administering dental care to anyone who has FOP. Overstretching of the jaw and intramuscular injections of local anesthetic must be avoided. Mandibular blocks cause muscle trauma that will lead to HO, and local anesthetic drugs are extremely toxic to skeletal muscle (Luchetti et al., 1996).

Falls suffered by FOP patients can lead to severe injuries and flare-ups. Patients with FOP have a self-perpetuating fall cycle. Minor soft tissue trauma often leads to severe exacerbations of FOP, which result in HO and joint ankylosis. Mobility restriction from joint ankylosis severely impairs balancing mechanisms, and causes instability, resulting in more falls (Glaser et al., 1998).

Falls in the FOP population are more likely to result in severe head injuries, loss of consciousness, concussions, and neck and back injuries, compared to people who do not have FOP. Individuals with FOP are often unable to use the upper limbs to absorb the impact of a fall. FOP patients are much more likely to be admitted to a hospital following a fall and have a permanent change in physical function because of the fall. In a group of 135 FOP patients, 67 percent of the reported falls resulted in a flare-up of the FOP. Use of a helmet by young patients may help reduce the frequency of severe head injuries that can result from falls (Glaser et al., 1998).

Measures to prevent falls should be directed at modification of activity, improvement in household safety, use of ambulatory devices (such as a cane, if possible), and use of protective headgear. Redirection of activity to less physically interactive play may also be helpful. Complete avoidance of high-risk circumstances may reduce falls, but also may compromise a patient's functional level and independence, and may be unacceptable to many. Adjustments to the living environment to reduce the number of falls within the home may include installing supportive hand-railings on stairs, securing loose carpeting, removing objects from walkways, and eliminating uneven flooring including doorframe thresholds. Prevention of falls due to imbalance begins with stabilization of gait. The use of a cane or stabilizing device may improve balance for many patients. For more mobile individuals, the use of a rolling cane or a walker will assist in stabilization.

When a fall occurs, prompt medical attention should be sought, especially when a head or neck injury is suspected. Any head or neck injury should be considered serious until proven otherwise. A few common signs and symptoms of severe head injury include increasing headache, dizziness, drowsiness, obtundation, weakness, confusion, or loss of consciousness. These symptoms often do not appear until hours after an injury. An FOP patient should be examined carefully by a healthcare professional if a head or neck injury is suspected.

As mentioned previously, prednisone use should be considered prophylactically following major soft tissue trauma, or peri-operatively. The dose of corticosteroids is dependent upon body weight. A typical dose of prednisone is 1-2 mg/kg/day (up to 100 mg), administered as a single daily dose for no more than 4 days (Table 1). In order to have the least suppressive effect on the hypothalamic-pituitary-adrenal axis, the medication should be given in the morning.

References

Glaser DL, Rocke DM, Kaplan FS. Catastrophic falls in patients who have fibrodysplasia ossificans progressiva. **Clin Orthop** 346: 110-116, 1998

Lanchoney TF, Cohen RB, Rocke DM, Zasloff MA, Kaplan FS. Permanent heterotopic ossification at the injection site after diphtheria-tetanus-pertussis immunizations in children who have fibrodysplasia ossificans progressiva. **J Pediatrics** 126: 762-764, 1995

Luchetti W, Cohen RB, Hahn GV, Rocke DM, Helpin M, Zasloff M, Kaplan FS. Severe restriction in jaw movement after route injection of local anesthetic in patients who have fibrodysplasia ossificans progressiva. **Oral Surg Oral Med Oral Pathol Oral Radiol Endod** 81: 21-25, 1996

3. Scalp Nodules in FOP

Scalp nodules are flare-ups on the head, commonly appearing in childhood – often the first post-natal manifestations of FOP. Scalp nodules are of little clinical significance despite their often large size and alarming appearance.

Scalp nodules are noted in very few publications (Kitterman et al., 2005; Piram et al., 2011; Kardile et al., 2012; Al Kaissi et al., 2016). They are often reported as first symptom of FOP, from the neonatal period (about 10% of cases (Kitterman et al., 2005), but also may be an under-recognized symptom at any age. The median age of onset is 1.5 years (Piram et al., 2011).

Clinically, scalp nodules may be solitary or numerous, immobile, with a variable size, from a walnut size to a great volume such as a tennis ball. They may be asymptomatic or painful only at onset. Usually, they appear and regress spontaneously, or can develop after trauma or infection, or in a child who is apparently in good health.

Radiographs are unnecessary but generally show soft-tissue thickening initially with small zones of HO after some months. Biopsies/surgical excision or fine-needle aspiration for cytological and histologic studies must be avoided. Histopathologic findings are described in three patients by Piram et al., 2011 as proliferation of short spindle-shaped cells in the deep subcutaneous tissue, with abundant collagenous stroma and scattered inflammatory cells (mast cells & T-cells) and numerous vessels.

The correlation between their presence and the genotype is not detailed in the few reported cases but it appears that they are associated with the R206H classical mutation in ACVR1 in numerous cases studied.

The occurrence of unique or multiple scalp nodule(s) in infancy is an important early sign of FOP and may be the first sign of a post-natal flare-up of the condition. The presence of scalp nodules during infancy should prompt immediate examination of the great toes – a clinical scenario that could appropriately accelerate the proper diagnosis of FOP.

So, importantly, when scalp nodules are seen, the toes must be examined! Even more importantly, biopsies must not be performed. Symptomatic treatments may be prescribed but steroids are not used as no joints are involved. Despite their often alarming appearance, no treatment is necessary. Swelling subsides with time – and if ossification occurs, remodeling is common as the lesions are incorporated into the growing skull.

References

Al Kaissi A, Kenis V, Ben Ghachem M, Hofstaetter J, Grill F, Ganger R, Kircher SG. The diversity of the clinical phenotypes in patients with fibrodysplasia ossificans progressiva. **J Clin Med Res** 8: 246-253, 2016

Kitterman JA, Kantanie S, Rocke DM, Kaplan FS. Iatrogenic harm caused by diagnosis errors in FOP. **Pediatrics** 116: 654-661, 2005

Kardile M, Nayak S, Nagaraja HS, Mishra AK. Fibrodysplasia ossificans progressiva in a four-year-old child. **J Orthop Case Rep** 2:17-20, 2012

Piram M, Le Merrer M, Bughin V, De Prost Y, Fraitag S, Bodemer C. Scalp nodules as a presenting sign of fibrodysplasia ossificans progressiva: a register-based study. **J Am Acad Dermatol** 64:97-101, 2011

4. Spinal Deformity in FOP

Spinal deformities are common in individuals who have FOP. A study in 40 FOP patients showed that 65 percent had radiographic evidence of scoliosis. The initial clinical abnormality was a rapidly developing scoliosis associated with a spontaneously occurring lesion in the paravertebral soft tissues. Once established, these deformities lead to rapid, permanent loss of mobility and to progressive spinal deformity with growth (Shah et al., 1994).

The formation of a unilateral osseous bridge along the spine prior to skeletal maturity limits growth on the ipsilateral side of the spine while growth continues uninhibited on the contralateral side. If an osseous bridge occurs bilaterally and the two bridges are relatively symmetrical, or if an osseous bridge forms after skeletal maturity, scoliosis will not result.

Severe scoliosis in FOP can lead to pelvic obliquity, similar to that seen in scoliosis resulting from other causes, and the obliquity can impair the balance of the trunk as well as standing and/or sitting balance.

Anecdotal experience in five patients suggests that traditional operative approaches to scoliosis in FOP patients can seriously exacerbate the disease. Furthermore, three patients in the series who had operative correction of the scoliosis continued to have progression of the spinal curve even after a spinal arthrodesis. In two of these patients, the arthrodesis was performed posteriorly and not anteriorly. Thus, continued anterior growth of the spine exacerbated rotational deformity.

Indications for correction of spinal deformity associated with more usual types of scoliosis do not pertain to patients with FOP. With the limited knowledge available, the risks of severe complications (most notably, the exacerbation of HO at sites remote from the operative field) that are associated with correction of spinal deformity in FOP likely outweigh the benefits (Shah et al., 1994). However, with greater knowledge of the natural history of FOP and newer surgical techniques, these old assertions are undergoing careful re-examination on a case-by-case basis.

A study of three patients with rapidly evolving chin-on-chest deformities suggests that a more aggressive surgical approach may be necessary to prevent and/or correct such rapidly progressive deformities in patients who have FOP (Moore et al., 2009).

References

- Moore R, Dormans J, Drummond DS, Shore EM, Kaplan FS, Auerbach J. Chin-on-chest deformity in patients who have fibrodysplasia ossificans progressiva (FOP). **J Bone Joint Surg Am** 91:1497-1502, 2009
- Shah P, Zasloff MA, Drummond, D, Kaplan FS. Spinal deformity in patients who have FOP. **J Bone Joint Surg Am** 76: 1442-1450, 1994

5. Cardiopulmonary Function in FOP

A recent natural history study showed that individuals with ACVR1R206H mutations have an increased prevalence of cardiac conduction abnormalities on electrocardiogram. Conduction abnormalities were present in 45.3% of baseline ECGs, with the majority of abnormalities classified as nonspecific intraventricular conduction delay (37.7%). More specifically, 22.2% of patients > 18 years old had conduction abnormalities, which was significantly higher than a prior published study of a healthy population (5.9%; n = 3978) ($p < 0.00001$). Patients with FOP < 18 years old also had a high prevalence of conduction abnormalities (62.3%). The 12-month follow up data was similar to baseline results. Conduction abnormalities did not correlate with chest wall deformities, scoliosis, pulmonary function test results, or increased Cumulative Analog Joint Involvement Scale scores. Echocardiograms from 22 patients with FOP revealed eight with structural cardiac abnormalities, only one of which correlated with a conduction abnormality (Kou et al., 2020).

In summary, individuals with FOP may have subclinical conduction abnormalities manifesting on ECG, independent of heterotopic ossification. Although clinically significant heart disease is not typically associated with FOP, and the clinical implications for cardiovascular risk remain unclear, knowledge about ECG and echocardiogram changes is important for clinical care and research trials in patients with FOP. Further studies on how ACVR1/ALK2^{R206H} affects cardiac health will help elucidate the underlying mechanism (Kou et al., 2020).

Patients with FOP develop thoracic insufficiency syndrome (TIS) that can lead to life-threatening complications. Features contributing to TIS in patients with FOP include:

- Costovertebral malformations with orthotopic ankylosis of the costovertebral joints
- Ossification of intercostal muscles, paravertebral muscles and aponeuroses
- Progressive spinal deformity including kyphoscoliosis or thoracic lordosis

Pneumonia, hypoxemia, hypercarbia, pulmonary hypertension and right-sided heart failure are the major life-threatening hazards that result from TIS in patients with FOP. Prophylactic measures to maximize pulmonary function, minimize respiratory compromise, and prevent influenza and pneumonia are helpful in decreasing the morbidity and mortality from TIS in patients with FOP (Kussmaul et al., 1998; Kaplan & Glaser, 2005; Kaplan et al., 2010). A pulmonologist should be involved early with regular spirometry assessments and sleep studies as needed.

Individuals with FOP develop progressive limitations in chest expansion, resulting in restrictive lung disease, with reduced vital capacity but no obstruction to air flow. Those with advanced disease have extremely limited chest expansion and rely on the diaphragm for inspiration (Kussmaul et al., 1998). The low inspiratory capacity results in low expiratory flow rates, in many cases.

Consequently, individuals with FOP are subject to atelectasis, retained secretions, hypoxemia, hypercarbia and pneumonia. All patients had abnormal spirometry secondary to TIS. Chest infection in the presence of diminished pulmonary reserve is the major hazard to life in patients with FOP. Many patients had abnormal electrocardiograms, with evidence of right ventricular dysfunction. It is suggested that the presence of severe restrictive disease of the chest wall is associated with a high incidence of right ventricular abnormalities (Kaplan et al., 2010).

Respiratory failure and cor pulmonale are features of severe TIS (Shah et al., 1974). A detailed description of this problem (Bergofsky et al., 1979) noted right ventricular hypertrophy in at least 10% of cases. Pulmonary hypertension was a common finding, which these authors attributed to increased vascular resistance and the effects of prolonged alveolar hypoventilation.

The respiratory problems seen in patients with FOP are similar to those seen in patients with respiratory muscle weakness such as cervical spinal cord injury, or other skeletal abnormalities such as kyphoscoliosis. Strategies similar to those used in these other populations to maximize respiratory muscle functional and clear secretions may be beneficial in those with FOP.

Inspiratory and expiratory muscle training should be routinely practiced and started at the age of diagnosis. A variety of incentive spirometers are available to encourage deep breathing. Inspiratory muscle training devices permit progressive resistance exercise training of the diaphragm.

Careful attention should be directed toward the prevention and therapy of intercurrent chest infections. Such measures should include prophylactic pneumococcal pneumonia and influenza vaccinations (given subcutaneously), chest physiotherapy, and prompt antibiotic treatment of early chest infection.

Upper abdominal surgery should be avoided if possible, as it interferes with diaphragmatic respiration. Sleep studies to assess sleep apnea may be helpful. Positive pressure assisted breathing devices such as BiPAP® (Bi-level positive airway pressure) masks without the use of supplemental oxygen may also be helpful. Night CPAP and noninvasive ventilation on ambient air may be effective treatments for nocturnal hypoventilation/hypoxemia.

Patients with FOP who have advanced TIS and who use unmonitored oxygen have a high risk of sudden death. Sudden correction of oxygen tension in the presence of chronic carbon dioxide retention suppresses respiratory drive. Patients who have FOP and severe TIS should not use supplemental oxygen in an unmonitored setting (Kaplan & Glaser, 2005; Kaplan et al., 2010).

During hospitalizations or in more advanced disease, individuals with FOP may have trouble clearing secretions. This can lead to atelectasis, pneumonia and respiratory failure requiring endotracheal intubation. Secretion clearance is enhanced by adequate hydration, guaifenesin, bronchodilators and mucolytics, as needed. If endotracheal intubation or a surgical procedure are considered, nasal fiberoptic intubation of the trachea is recommended (Kilmartin et al. 2014). For surgical or interventional procedures, a carefully designed anesthesia plan is paramount. Planning for extubation of the trachea should be weighed against creation of tracheostomy if impending respiratory failure is expected due to the advanced TIS. Postoperative care should be assigned to an intensive care setting.

There is also much that can be done in prevention. Individuals with FOP are often born with congenital malformations of the costovertebral joints that cause some degree of chest restriction even before the appearance of heterotopic bone, although these restrictions may not lead to any clinical problems early in life. However, because of these restrictions, individuals with FOP are more likely to rely, even early in life, on diaphragmatic breathing. It is recommended that individuals with FOP be evaluated by a pulmonologist by the end of the first decade of life in order to perform baseline pulmonary function tests and echocardiograms. The results of these tests may further help guide preventative care for the cardiopulmonary system.

Several devices are available to loosen secretions from relatively simple handheld devices that cause vibration of the airway walls during exhalation, to garments that vibrate the chest wall to high technology specialty beds that turn and oscillate. Care must be taken when using such devices in patients with a weak cough, as they may be unable to expectorate the secretions once loosened. Use of mechanical insufflation-exsufflation can non-invasively extract retained secretions from individuals with ineffective cough. The device can dramatically increase peak cough expiratory flow in individuals with impaired expiratory muscle function. Combining a method to loosen secretions with in-exsufflation to remove them may prevent respiratory failure and the need for mechanical ventilation. However, all percussive devices should be used with caution due to risk of inducing trauma.

Various activities can help maximize the strength of the diaphragm and perhaps decrease the risk of intercurrent pulmonary problems. In addition to the intermittent use of incentive spirometry, other activities such as deep breathing, swimming/hydrotherapy, and singing, should be encouraged at an early age and may help improve long-term pulmonary function.

References

Bergofsky EH. Respiratory failure in disorders of the thoracic cage. **Am Rev Resp Dis** 119:643–669, 1979

Kaplan FS, Glaser DL. Thoracic insufficiency syndrome in patients with fibrodysplasia ossificans progressiva. **Clin Rev Bone Miner Metab** 3: 213-216, 2005

Kaplan FS, Zasloff MA, Kitterman JA, Shore EM, Hong CC, Rocke DM. Early mortality and cardiorespiratory failure in patients with fibrodysplasia ossificans progressiva. **J Bone Joint Surg Am** 92: 686-691, 2010

Kilmartin, E, Grunwald, Z, Kaplan FS, Nussbaum BL. General anesthesia for dental procedures in patients with fibrodysplasia ossificans progressiva: A review of 42 cases in 30 patients. **Anesth Analg** 118: 298-301, 2014

Kou S, De Cunto C, Baujat G, Wentworth KL, Grogan DR, Brown MA, Di Rocco M, Keen R, Al Mukaddam M, le Quan Sang KH, Masharani U, Kaplan FS, Pignolo RJ, Hsiao EC. Patients with ACVR1(R206H) mutations have an increased prevalence of cardiac conduction abnormalities on electrocardiogram in a natural history study of fibrodysplasia ossificans progressiva. **Orphanet J Rare Dis.** 2020 Jul 29;15(1):193. doi: 10.1186/s13023-020-01465-x.

Kussmaul WG, Esmail AN, Sagar Y, Ross J, Gregory S, Kaplan FS. Pulmonary and cardiac function in advanced fibrodysplasia ossificans progressiva. **Clin Orthop** 346: 104-109, 1998

Shah PB, Zasloff MA, Drummond D, Kaplan FS. Spinal deformity in patients who have fibrodysplasia ossificans progressiva. **J Bone Joint Surg Am** 76:1442–1450, 1994

6. Respiratory Health in FOP

Strong respiratory health is important for everyone. This is particularly true for individuals with FOP since FOP can severely decrease respiratory capacity from the chest wall deformities, heterotopic ossification and scoliosis (Shah et al.,1994; Towler et al., 2020; Botman et al, 2021).

Maintaining strong respiratory health involves a few things:

Infection precautions, particularly during the flu season: Make sure that all FOP patients and their family members wash their hands regularly and use alcohol gel. Avoid places where infection can be easily transmitted. In the event that exposures need to occur, we recommend that individuals with FOP wear a simple surgical mask to decrease the risk of breathing-in infected droplets (such as from a sneeze). These masks are not meant to filter out all viruses and infectious bacteria, but will balance the need to decrease exposure to larger droplets with comfortable breathing.

Maintaining respiratory capacity: We recommend 15-30 minutes per day of active respiratory activity. This should not be uncomfortable or cause pain, but is meant to help keep the diaphragm and other respiratory muscles healthy. Activities that we recommend include vigorous vocalizations (i.e. singing, as in a choir; loud continuous vocal activity like singing in the shower).

For some, an incentive spirometer can complement vigorous vocalizations. These devices can be used to measure lung capacity. However, we recommend using them as a way to maintain lung capacity and make sure the lungs are well-ventilated.

FOP patients who decide to have yearly flu immunizations should use the subcutaneous immunization, given by an experienced provider. The flu immunization should not be given during a flare-up and not until

6-8 weeks after a flare-up has resolved. Whether or not the FOP patient decides to get a flu vaccine, all immediate family members, household contacts and caretakers should be immunized.

In the case where the flu vaccine is not obtained, for whatever reason, having a ready supply of Oseltamivir (Tamiflu) on hand during flu season is a reasonable precaution. At the first signs of the flu (fever or feeling feverish/chills, cough, sore throat, runny or stuffy nose, muscle or body aches, headaches, fatigue (tiredness), vomiting and diarrhea), one should take the first dose of Oseltamivir and then immediately contact their physician (Jefferson et al., 2014).

There are many types of incentive spirometers available and many different strategies for maintaining lung function. The IFOPA provides two types depending on age and jaw needs.

Peak Flow Whistle (for young children)

For young children, a peak flow whistle is recommended. These whistles will make a sound when air is blown fast enough through the whistle. The most important part of this device is taking the deep breath beforehand – not the actual ability to generate the whistle sound!

The patient should:

1. Sit upright or stand.
2. Place the whistle in the mouth, and make sure the lips are tightly sealed
3. Slowly inhale as much as possible (this is the most important part). Hold the breath for about 10 seconds.
4. Exhale quickly through the whistle to generate the sound.
5. Rest in between breaths.
6. Repeat 10 times, with short rest breaks in between.
7. The patient should stop if they feel dizzy at any time, or if they have any tenderness or chest discomfort.

The whistle should be set based on the patient's estimated peak flow on a regular day (i.e. should just be able to whistle). Standard tables with FEV1 values are not useful in FOP due to the presence of chest deformities; however, prior PFT values can serve as a guide. The goal is to encourage deep breaths to minimize atelectasis, rather than increasing peak flow. The flow whistle serves as an incentive for children.

Incentive Spirometer

The incentive spirometer is for older children and adults. There are many models available. The goal however is the same with all the models - to take slow, deep breaths to expand the lungs.

The patient should:

1. Sit upright in a chair or bed, or stand upright.
2. Hold the spirometer in front of the face at eye level. Many FOP patients will not be able to do this due to ankylosis of the joints in the upper extremities. They may need assistance or have the spirometer positioned close enough to use but without having to hold with both hands.
3. Close your lips around the mouthpiece to make a seal.
4. Slowly exhale completely.

5. Slowly inhale thorough the mouth as deeply as possible.
6. The piston will rise with inhalation.
7. Hold the breath for 10 seconds (the piston may fall during this time), then exhale.
8. Repeat 10 times, with short rest breaks in between.
9. Stop and rest, if they feel dizzy at any time.
10. Perform this routine twice daily.

References

Botman E, Smilde BJ, Hoebink M, Treurniet S, Raijmakers P, Kamp O, Teunissen BP, Bökenkamp A, Jak P, Lammertsma AA, van den Aardweg JG, Boonstra A, Eekhoff EMW. Deterioration of pulmonary function: An early complication in Fibrodysplasia Ossificans Progressiva. **Bone Rep.** 2021 Feb 25;14:100758. doi: 10.1016/j.bonr.2021.100758. PMID: 33748352; PMCID: PMC7972965

Jefferson T, Jones MA, Doshi P, Del Mar CB, Hama R, Thompson MJ, Spencer EA, Onakpoya I, Mahtani KR, Nunan D, Howick J, Heneghan CJ. Neuraminidase inhibitors for preventing and treating influenza in healthy adults and children. **Cochrane Database Syst Rev.** 2014 Apr 10;(4):CD008965. doi: 10.1002/14651858.CD008965.pub4. Review

Shah PB, Zasloff MA, Drummond D, Kaplan FS. Spinal deformity in patients who have fibrodysplasia ossificans progressiva. **J Bone Joint Surg** 76-A: 1442-1450, 1994

Towler OW, Shore EM, Kaplan FS. Skeletal malformations and developmental arthropathy in individuals who have fibrodysplasia ossificans progressiva. **Bone.** 2020 Jan;130:115116. doi: 10.1016/j.bone.2019.115116. Epub 2019 Oct 23.

7. Immunizations for Diseases other than Influenza in FOP

Vaccines against various infectious diseases have dramatically decreased morbidity and mortality from infectious diseases (Roush et al., 2007). Because individuals with FOP are subject to the same infectious diseases as the general population, immunizations are essential in FOP. However, there are several major considerations and precautions regarding immunization of those with FOP, and these are discussed below.

The Advisory Committee on Immunization Practices (ACIP) of the Center for Disease Control and Prevention (CDC) has published charts with their recommendations for immunization for infants, children, adolescents, and adults. These charts can be found at: <https://www.cdc.gov/vaccines/schedules/> In addition, this site contains a wealth of other information about immunizations including Parent Friendly Immunization Charts, Resources for Parents, Resources for Adults, Resources for Health Professionals, Vaccine Information Statements, and up to date clinical information about Covid-19 vaccines. Hard copies of the Immunization Charts can be obtained for free using this site.

These immunization recommendations, last updated in July, 2021, are approved by the American Academy of Pediatrics, the American Academy of Family Practitioners, and the American College of Obstetricians and Gynecologists.

For most of the vaccines given in childhood, the ACIP recommends intramuscular (IM) administration. However, IM injections are contraindicated in FOP because of the risk of heterotopic ossification (HO) at the injection site and, in some cases, elsewhere in the body. Lanchoney and associates (1995) reported that IM injection of diphtheria-pertussis-tetanus (DPT) vaccines caused flare-ups and subsequent HO in 27% of

children with FOP and, in some cases, permanent loss of joint motion (Lanchoney et al., 1995).

Furthermore, subcutaneous (SubQ) injection of DPT type vaccines may also cause flare-ups, HO and loss of joint mobility (F. Kaplan, personal communication). Therefore, it seems that some unidentified component(s) of DPT type vaccines may cause flare-ups and subsequent HO in individuals with FOP regardless of route of administration. Given these experiences, it is recommended that no DPT type vaccines be given to individuals with FOP.

Other immunizations given by the SubQ route have not been reported to cause flare-ups or HO in individuals with FOP. Specifically, there have been no reported cases of flare-ups following subcutaneous immunization with the MMR or MMRV vaccines despite the fact that they contain attenuated viruses.

In individuals with hemophilia, IM injections may cause hemorrhage. Because of this risk, the World Federation for Hemophilia recommends SubQ immunization for individuals with hemophilia (Guidelines for the Management of Hemophilia, 2012), and it is standard practice at most Hemophilia Treatment Centers to recommend SubQ administration of all vaccines (Ragni et al., 2000; Ritchey, 2005; Carpenter et al., 2015; Schaefer et al., 2017). However, of the vaccines recommended for IM administration and given SubQ to hemophilia patients, to date only Hepatitis A (Ragni et al., 2000), Hepatitis B (Carpenter et al., 2015), and diphtheria-tetanus (Cook, 2008; Schaefer et al., 2017) vaccines have been shown to be effective in providing immunity. There are no published data regarding the effectiveness of other IM vaccines that are given SubQ.

A concern for giving several of the vaccines SubQ has been granuloma formation at the injection site (Pembroke & Marten, 1979; Bergfors et al., 2003). These granulomas are considered to be the result of hypersensitivity to aluminum, an adjuvant to the other components of the vaccine. In a prospective cohort study in Sweden, Bergfors and associates reported that long lasting, intensely itching granulomas occurred in only about 1% of children receiving IM injections of diphtheria-tetanus-pertussis-polio-Haemophilus influenza type B and pneumococcal conjugate vaccines (Bergfors et al., 2014), an incidence similar to their previous study of SubQ immunization using vaccines against the same infectious diseases (Bergfors et al., 2003). Furthermore, granulomas have not been reported to be a problem with SubQ vaccines administered to patients with hemophilia (Ritchey, 2005; J. Huang, personal communication). We are not aware of granuloma formation after any immunizations in individuals with FOP.

Based on the above information, it may seem reasonable to recommend that individuals with FOP receive all their recommended immunizations by SubQ injection. However, the situation is more complicated than that. Several of the routine vaccines are conjugated with components of either diphtheria or tetanus vaccines. Because the component(s) in DPT type vaccines that cause FOP flare-ups and HO have not been identified, it may be prudent for FOP patients to avoid those vaccines that are conjugated with components of DPT vaccines (See Sections 4 and 5 below).

Recommendations for Immunization in FOP:

The following sections list the vaccines recommended by the ACIP for routine immunization of individuals from birth to 18 years of age and for adults along with our cautions regarding administration to individuals with FOP. The median age of diagnosis of FOP is just under age six years (Kitterman et al., 2005). Therefore, many of the vaccines will have already been administered IM by the time that the person has been diagnosed with FOP.

General Recommendation: Do not give any immunizations to individuals with FOP during a flare-up and not until 6 to 8 weeks after the flare-up has resolved.

Recommendations Regarding Specific Vaccines:

1. Vaccines recommended by the ACIP to be given SubQ to all and appear to be safe for FOP patients:

- Measles, Mumps, Rubella Vaccine (MMR).
- Varicella Vaccine (VAR)
- Measles, Mumps, Rubella, Varicella Vaccine (MMRV; brand name: ProQuad)
- Inactivated Polio Vaccine (IPV)
- Pneumococcal 23-valent Polysaccharide Vaccine (PPSV23; brand name: Pneumovax-23)

2. Vaccines recommended by the ACIP to be given IM but are effective SubQ and are probably safe for FOP patients: (These contain no components of diphtheria or tetanus.)

- Hepatitis A Vaccine (HepA; brand names: Havrix, VAQTA)
- Hepatitis B Vaccine (HepB; brand names: Energix-B; Recombivax-HB)

3. Vaccines recommended by the ACIP to be given IM and are probably safe for FOP patients, but there are no data on their effectiveness when given SubQ: (These contain no components of diphtheria or tetanus.)

- Meningococcal serogroup B Vaccine (MenB; brand names: Bexsero; Trumenba)
- Human Papilloma Virus Vaccine (HPV; brand names: Gardasil; Gardasil-9)

4. Vaccines recommended by the ACIP to be given IM, but there are no data on their effectiveness when given SubQ, and these vaccines may NOT be safe for FOP patients because they are conjugated to a component of diphtheria or tetanus:

- Haemophilus influenzae type B vaccine (HiB; brand names: Hiberix; Act HiB)
- Meningococcal serogroups A, C, W, Y (brand names: Menactra; Menveo)
- Pneumococcal 13-valent conjugate vaccine (PCV13; brand name: Prevnar-13)
- HiB/MenC combination vaccine (brand names: Menitorix; Menhibrix)

5. Diphtheria, Pertussis, Tetanus type Vaccines:

These vaccines are not routinely recommended in FOP because of the experience that they may cause flare-ups, HO, and permanent loss of joint motion (Lanchoney et al., 1995; F. Kaplan, personal communication). Therefore, certain precautions should be taken to avoid or treat the diseases that these vaccines prevent. However, there may be certain situations where the vaccine needs to be given to prevent life threatening illness (See Section C, below):

- Diphtheria*** is a rare disease with only 2 cases (both non-fatal) being reported in the United States in the past 10 years. If diphtheria is suspected clinically, follow the diagnosis and treatment guidelines of the CDC (<https://www.cdc.gov/diphtheria/clinicians.html>) and the American Academy of Pediatrics, Diphtheria, 2018.
- Pertussis*** is a particular risk for infants and those with respiratory compromise (common in FOP). All household contacts of individuals with FOP should be immunized for pertussis. If there is a local outbreak of pertussis, those with FOP should not attend school during the outbreak. If pertussis is suspected in an individual with FOP, start early treatment with antibiotics as recommended by the CDC (<https://www.cdc.gov/pertussis/clinical/treatment.html>) and the American Academy of Pediatrics, Pertussis, 2018. If a household contact is diagnosed with pertussis, the individual with FOP should be given post-exposure prophylaxis.

- C. **Tetanus.** In case of a wound considered a risk for tetanus, follow the guidelines for “Wound Management for Tetanus Prevention” of the CDC (<https://www.cdc.gov/tetanus/clinicians.html>) and the American Academy of Pediatrics, Tetanus, 2018. In addition, it is recommended that consultation be obtained with a specialist in infectious diseases. The use of Tetanus Immune Globulin (TIG) given subcutaneously should be considered for acute management.

Additional considerations for FOP include:

1. If TIG is to be given IM, the injection site should be chosen to be near joints or muscles that have already lost function. This may be a non-standard site. Thus, if a flare-up develops, it is less likely to worsen mobility significantly. Alternatively, TIG can be given SubQ, but the efficacy is unknown. However, recent data in immunocompromised patients show that immunoglobulins can be effectively delivered SubQ.
2. Because the IM injection of TIG may precipitate a flare-up, give prophylactic prednisone 2 mg/kg/day (up to a maximum of 100 mg/day) for 2 days. Then taper the daily dose by 50% every other day. Note that this is shorter than the usual course for treatment of a flare-up, which is usually 4 days at 2 mg/kg/day. Prophylactic prednisone is recommended only with TIG and is not necessary for other immunizations.
3. Because the IM injection can cause significant inflammation, give ibuprofen immediately prior to the injection and continue with standard age/weight appropriate dosing for 7 days, even if no symptoms are present.
4. In the event that TIG is not available and the only option is to use a Td containing vaccine, the Td vaccine should be given SubQ and the patient with FOP should be given prophylactic prednisone 2 mg/kg/day (up to a maximum of 100 mg/day) for 2 days. Then taper the daily prednisone dose by 50% every other day. Note that this is shorter than the usual course for treatment of a flare-up, which is usually 4 days at 2 mg/kg/day followed by a daily taper.
6. **Rotavirus Vaccines (*Rotarix, RotaTeq*)** are oral vaccines that contain live virus. The CDC recommends these vaccines for infants 2 to 6 months of age to prevent gastroenteritis caused by Rotavirus. Because the majority of those with FOP are not diagnosed until later in life, many with FOP will already have received one of these vaccines before FOP has been diagnosed. We recommend that Rotavirus vaccines not be given if FOP has been diagnosed in infancy.

7. Other vaccines

- A. **Covid-19 Vaccines.** See section 9: Coronavirus (COVID-19) Precautions & Guidance for FOP Patients & Families
- B. **Zoster Vaccine.** The ACIP recommends Zoster Vaccine only for individuals 50 years of age and older to prevent Shingles (Herpes Zoster), which is due to reactivation of the Zoster-Varicella virus that causes Chickenpox. There are two vaccines available. Vostarax is a live vaccine and should not be given to those with FOP. Shingrix is a recombinant vaccine that contains no live virus. For individuals with FOP 50 years of age and older Shingrix should be given SubQ.

- C. *Japanese Encephalitis Vaccine (JE-Vax)* is routinely given in several Asian countries where there is a high risk of this disease. This vaccine is given SubQ (<https://www.rxlist.com/je-vax-drug.htm#description>) There is an older form of Japanese Encephalitis vaccine (JE-VC, Ixiaro) that is administered IM; this vaccine should not be given to individuals with FOP.
- D. *Tuberculosis: Bacille Calmette-Guerin (BCG) Vaccine* is routinely given to infants to prevent tuberculosis in countries and areas where there is a high risk for the disease. Depending on the preparation, BCG can be given percutaneously with a multiple puncture device. (<https://www.fda.gov/downloads/biologicsbloodvaccines/vaccines/approvedproducts/ucm202934.pdf>) or injected intradermally. (http://www.who.int/immunization_standards/vaccine_quality/118_bcg/en/)
- E. *Typhoid Fever*: The World Health Organization (WHO) recommends immunization for protection against Typhoid Fever only for individuals in areas where there is a high risk for the disease. The only WHO recommended Typhoid vaccine is Typbar Vi Conjugated Vaccine. (<https://www.who.int/news/item/03-01-2018-typhoid-vaccine-prequalified>) Because the vaccine contains components of Tetanus Toxoid, it is not recommended for those with FOP. Individuals with FOP, who plan to travel to areas where there is a high risk of Typhoid, should consult with their physician to decide whether the risk of Typhoid is greater than the risk of the vaccine.
- F. *Yellow Fever Vaccine (YF-VAX)* is recommended for persons age 9 months and older who are traveling to or living in areas at risk for Yellow Fever transmission in South America and Africa. This vaccine is given SubQ (<https://www.cdc.gov/mmwr/preview/mmwrhtml/rr5907a1.htm>). At this time there is limited availability of this vaccine. Another Yellow Fever Vaccine (Stamaril) is a live virus vaccine and should not be given to those with FOP.

References

American Academy of Pediatrics, Diphtheria. In: Kimberlin DW, Brady MT, Jackson MA, Long SS, eds. **Red Book: 2018 Report of the Committee on Infectious Diseases. 31st ed.** Itasca, IL: American Academy of Pediatrics, pps. 319-323, 2018

American Academy of Pediatrics, Pertussis. In: Kimberlin DW, Brady MT, Jackson MA, Long SS, eds. **Red Book: 2018 Report of the Committee on Infectious Diseases. 31st ed.** Itasca, IL: American Academy of Pediatrics, pps. 620-634, 2018

American Academy of Pediatrics, Tetanus. In: Kimberlin DW, Brady MT, Jackson MA, Long SS, eds. **Red Book: 2018 Report of the Committee on Infectious Diseases. 31st ed.** Itasca, IL: American Academy of Pediatrics, pps. 793-798, 2018

Bergfors E, Hermansson G, Nystrom-Kronander U, Falk L, Valter L, Trollfors B. How common are long-lasting, intensely itching vaccination granulomas and contact allergy to aluminium induced by currently used pediatric vaccines? A prospective cohort study. **Eur J Pediatr** 173: 1297-1307, 2014

Bergfors E, Trollfors B, Inerot A. Unexpectedly high incidence of persistent itching nodules and delayed hypersensitivity to aluminium in children after the use of adsorbed vaccines from a single manufacturer. **Vaccine** 22:64-69, 2003

Carpenter SL, Soucie JM, Presley RJ, Ragni MV, Wicklund BM, Silvey M, Davidson H. Hepatitis B vaccination is effective by subcutaneous route in children with bleeding disorders: a universal data collection database analysis. **Haemophilia** 21: e39-e43, 2015

Cook IF. Evidence based route of administration of vaccines. **Hum Vaccin** 26: 67-73, 2008

Guidelines for the Management of Hemophilia, 2nd Ed. World Federation of Hemophilia, Montreal, Canada, p. 23, 2012

Kitterman JA, Kantanie S, Rocke DM, Kaplan FS. Iatrogenic harm caused by diagnostic errors in fibrodysplasia ossificans progressiva. **Pediatrics** 116: e654-e651, 2005

Lanchoney TF, Cohen RB, Rocke DM, Zasloff MA, Kaplan FS. Permanent heterotopic ossification at the injection site after diphtheria-tetanus-pertussis immunizations in children who have fibrodysplasia ossificans progressiva. **J Pediatr** 126: 762-764, 1995

Pembroke AC and Marten RH. Unusual cutaneous reactions following diphtheria and tetanus immunization. **Clin Exp Dermatol** 4:345-348, 1979

Ragni MV, Lusher JM, Koerper MA, Manco-Johnson M, Krause DS. Safety and immunogenicity of subcutaneous hepatitis A vaccine in children with haemophilia. **Haemophilia** 6: 98-103, 2000

Ritchey AK. Administration of vaccines to infants and children with hemophilia. A survey of Region III comprehensive hemophilia treatment centers. **Blood** 106: 4079, 2005

Roush SW, Murphy TV, and the Vaccine-Preventable Disease Table Working Group. Historical comparisons of morbidity and mortality for vaccine-preventable diseases in the United States. **JAMA** 298: 2155-2163, 2007

Schaefer BA, Gruppo RA, Mullins ES, Tarango C: Subcutaneous diphtheria and tetanus vaccines in children with haemophilia: a pilot study and review of the literature. **Haemophilia** 23: 904-909, 2017

8. Immunizations for Influenza in FOP

Influenza (“the flu”) is a major cause of morbidity and mortality worldwide. It is especially dangerous for those with FOP (Scarlett et al., 2004). Every year, flu vaccines are produced based on the predicted strains that will be prevalent in the following cycle. The Centers for Disease Control and Prevention (CDC) recommend flu vaccinations by the end of October in the United States. Other countries may have different schedules and types/brands of vaccines available. Timing of the vaccinations should be determined with the local health care provider.

The most common forms of flu vaccinations are administered intramuscularly (IM) or provided as a live attenuated virus delivered in an intranasal form. In some years, transdermal and intradermal flu vaccines (given via a patch through the skin, or injected just under the skin but not into the deeper tissues) may be available.

Live attenuated flu vaccines are not recommended

The live attenuated intranasal form of the flu vaccine (such as Flumist® in the United States) has been reported to be associated with flares in some patients with FOP (F. Kaplan, Personal communication). This intranasal vaccine is not recommended for this reason.

Transdermal or intradermal vaccines are preferred, when available

If transdermal or intradermal forms of the flu vaccine are available, we recommend, as we have for many years, using those routes. Information about the seasonal influenza flu vaccine can be found on the CDC website: <https://www.cdc.gov/flu/vaccines/index.htm>

Subcutaneous alternative for flu vaccine administration

In years when the transdermal or intradermal forms are not available, we recommend that people living with FOP receive the flu vaccine using a modified protocol where the regular flu vaccine is given subcutaneously. Although there is no clear data as to how efficacious this is, prior studies suggest that there will be some efficacy despite being administered in a different route. Note that this will likely require a physician or physician's office to administer the flu vaccine, as many places (i.e. pharmacies) will not deviate from their normal protocol of intramuscular injection.

- For children, have one dose (typically 0.25 ml, depending on the formulation) of the intramuscular vaccine administered subcutaneously. Do not deliver the vaccine intramuscularly.
- For adults, either have two doses of the pediatric dose (typically 0.25 ml each) intramuscular vaccine administered subcutaneously, at two different locations. Alternatively, have the regular adult dose (typically 0.5 ml, depending on the formulation) split and administered as two separate subcutaneous injections at two different locations. The locations do not need to be far apart. Injection of 0.5 ml subcutaneously in any location may be uncomfortable. The ICC does NOT recommend to take the vaccine intramuscularly.

For all vaccinations in persons living with FOP, it is recommended that an injection site be chosen near a joint or muscle group that has already been affected by HO, and in a location that would not cause complications if heterotopic bone was to form. That way, if a flare does develop, it is less likely to result in loss of mobility. For all patients, it is recommended to take a dose of acetaminophen or ibuprofen with the vaccine to help with any discomfort that the vaccine may cause.

Family members living in the same home and caretakers should get the standard intramuscular flu vaccination on schedule. The nasal flu spray is NOT recommended for those in close contact with individuals living with FOP because the attenuated virus, though weaker, can still give a mild case of the flu to contacts.

Please keep in mind that those living with FOP should avoid flu immunizations during an active flare-up – even a subcutaneous vaccine should NOT be given anywhere.

Antivirals – Oseltamivir/Tamiflu

If a person living with FOP or anyone living with or caregiving for a person with FOP develops symptoms suggestive of the flu, they should get prompt evaluation and consider antiviral treatment (i.e. oseltamivir, Tamiflu®). Oseltamivir is only effective against influenza and does not work against the common cold or other viruses. The effectiveness of oseltamivir is highest in the early phase of an infection, so prompt medical attention is important when symptoms start (typically a combination of high fever and upper

respiratory symptoms). Nasal swab testing may be needed to confirm infection with influenza. Oseltamivir does not have a long shelf life, so we generally recommend that a prescription be available “on hold” at a 24-hr pharmacy and that the medication be started once influenza infection has been confirmed by a medical care provider (Jefferson et al., 2014).

Infection Prevention for Everyone

Everyone should practice everyday preventive actions to stop the spread of germs as shared by the CDC on their website at <https://www.cdc.gov/flu/protect/preventing.htm>.

1. Try to avoid close contact with sick people.
2. While sick, limit contact with others as much as possible to keep from infecting them.
3. If you are sick with flu symptoms, CDC recommends that you stay home for at least 24 hours after your fever is gone except to get medical care or for other necessities. (Your fever should be gone for 24 hours without the use of a fever-reducing medicine.)
4. Cover your nose and mouth with a tissue when you cough or sneeze. Throw the tissue in the trash after you use it.
5. [Wash your hands](#) often with soap and water. If soap and water are not available, use an [alcohol-based hand rub](#).
6. Avoid touching your eyes, nose and mouth. Germs spread this way.
7. Clean and disinfect surfaces and objects that may be contaminated with germs like the flu.
8. See [Everyday Preventive Actions](#) and [Nonpharmaceutical Interventions \(NPIs\)](#) for more information about actions – apart from getting vaccinated and taking medicine – that people and communities can take to help slow the spread of illnesses like influenza (flu).

References

Jefferson T, Jones MA, Doshi P, Del Mar CB, Hama R, Thompson MJ, Spencer EA, Onakpoya I, Mahtani KR, Nunan D, Howick J, Heneghan CJ. Neuraminidase inhibitors for preventing and treating influenza in healthy adults and children. **Cochrane Database Syst Rev.** 2014 Apr 10;(4):CD008965. doi: 10.1002/14651858.CD008965.pub4. Review

Scarlett RF, Rocke DM, Kantanie S, Patel JB, Shore EM, Kaplan FS. Influenza-like viral illnesses and flare-ups of fibrodysplasia ossificans progressiva (FOP). **Clin Orthop Rel Res** 423: 275-279, 2004

9. Coronavirus (COVID-19) Precautions & Guidance for FOP Patients & Families

This section focuses on COVID-19 vaccination recommendations as of January 10, 2022. Patients, physicians, caretakers, other healthcare workers and family members should consult the ICC website (www.iccfop.org) for the latest guidance in this area.

The Coronavirus (COVID-19) pandemic continues to pose significant risks to the population worldwide - including the FOP community - with new variants of SARS-CoV-2 virus emerging. **The ICC recommends that people living with FOP to continue to follow strict precautionary measures to prevent infection from SARS-CoV-2, the virus that causes the COVID-19 illness.**

The recommendations regarding COVID-19 infection and COVID-19 vaccinations to the general public are changing rapidly, are country and locale specific, and based on COVID-19 vaccine and treatment availability:

- **UNCHANGED!** The ICC does not provide recommendations on whether any individual patient with FOP should or should not receive a COVID vaccine. Vaccination for COVID should not be required for people living with FOP due to potential risk of flare up, but those who chose to do get the vaccination should follow the guidelines below. Discuss with your physician whether vaccination may be appropriate for you or your family.
- **UNCHANGED!** The decision to take a vaccine is a **personal one** and based on the balance of risks and benefits, and this should be discussed with your medical team. The ICC continues to recommend that COVID-19 vaccines be administered by the same route for which it was approved (i.e., intramuscular, if the vaccine was designed that way).
- **New!** Reviewing preliminary data shared by Dr Hsiao as a pre-print, [Social and Clinical Impact of COVID-19 on Patients with Fibrodysplasia Ossificans Progressiva - PubMed \(nih.gov\)](#)
 - Among 15 FOP patients who received intramuscular COVID-19 vaccination, the most common symptoms were pain/soreness at the injection site, tiredness and swelling which is similar to the reported symptoms in the general population. 1 out of 15 individuals with FOP that self-selected to receive the COVID-19 vaccination developed symptoms of a flare-up, which was managed by prednisone. None of the 15 patients required hospitalization.
 - Among 10 FOP patients with COVID-19 infection, the most common symptoms were fatigue, loss of taste or smell and cough which is similar to the symptoms reported in the general population. 2 out 10 FOP patients developed flare-ups and 1 FOP patient was hospitalized.
 - Information regarding FOP and COVID-19 remains very limited and Dr Hsiao's paper does not include all FOP patients who have received the COVID-19 vaccines or had COVID-19 infection.
- **New!** In certain countries, vaccines are now available for children age 5 or over. The ICC does not provide recommendations on whether a patient with FOP should or should not receive a COVID vaccine. The COVID vaccines are not available in all countries for children aged 5 and over. Discuss with your physician whether the vaccine is appropriate for your child.
- **New!** ICC **does not provide recommendations for or against** the booster vaccination. Please consult with your medical team prior to receiving the booster to discuss if a booster is appropriate and safe for you.
- **New!** Patients with FOP are at high risk of complications with COVID-19 infection and should discuss with their medical team if the use of monoclonal antibodies or anti-retroviral medications would be beneficial, in the event of a SARS-CoV-2 infection.
 - Monoclonal antibodies are often given intravenously and are approved for adults and pediatric patients (specific populations and age ranges vary). Antibodies are in short supply and may require meeting specific criteria, including age, infection status, and risk of complications, as well as the specific strain of SARS-CoV-2. In general, patients with FOP are not considered immunocompromised, but are at increased risk from COVID due to pulmonary complications. These interventions should be started as early as possible and usually within 5-10 days of symptoms onset.

- Anti-retroviral medicines (such as Molnupiravir or Paxlovid) are pills or injections that have been approved in some countries such as the United States and United Kingdom, and are used for decreasing the severity of infection. They may need to be administered within 5 days of symptoms onset. Paxlovid or other therapies may be available as pre-exposure prophylaxis for certain populations. Discuss with your primary care physician to assess eligibility and appropriateness.
 - Again, availability and recommendations of the use of these treatments are rapidly changing and country/location specific. Please consult with your local medical team for advice and access to these medications.
- **New!** Growing data indicates that patients who have had a prior COVID infection are not well protected from subsequent infections. Continuing universal precautions is important, and patients should discuss with their physician if getting vaccinated/boosted is appropriate.

Important! Blood antibody testing is not considered a reliable measure of protection against SARS-CoV-2 infection. It measures that a patient has been exposed and had an immune response, but it is not clear how an antibody titer correlates with protection status.

Important! Please consider being part of the observational clinical study for patients who have been exposed or diagnosed with COVID, or who are considering the COVID vaccine. This study is led by Dr Edward Hsiao at UCSF. Please contact him at edward.hsiao@ucsf.edu if you are interested in learning more.

Important! If you decide to take the COVID vaccine, the ICC recommends:

DO NOT TAKE ANY VACCINATION IF YOU ARE HAVING A FLARE-UP; WAIT AT LEAST TWO WEEKS UNTIL AFTER THE FLARE-UP RESOLVES.

- **Discuss your plans with your doctor.** Review any potential allergies or prior reactions like anaphylaxis that you should consider before taking the vaccine. Based on the US CDC guidelines, a patient can receive COVID vaccination as soon as 2 weeks after a COVID infection.
- **Take the vaccine via the recommended route and dose** (ie **intramuscular** for the currently available vaccines). Safety and efficacy of taking an IM vaccine through the subcutaneous route is not known, and could cause a more unexpected inflammatory response or poor immune response, and is currently not recommended.
- If possible, take the vaccine in a **location that is already fused**, as the vaccines all appear to induce some local site reaction (arm pain and swelling). For example, if your left hip or right shoulder are fused, you should use the muscle around those sites.
- Patients with FOP should be **flare free for at least 2 weeks** prior to receiving the vaccine.
- Have the injection done by an experienced nurse, physician, or pharmacist.
- The clinician should be aware that patients with FOP may have hidden HO and thinned muscle at the site of the injection. Avoid injecting directly next to existing HO bone if possible.
- Prior to the vaccination, **have ibuprofen or acetaminophen available**. Also, have a course of prednisone for flares available.

- Prednisone and other glucocorticoids could decrease the efficacy of the vaccine, please consult with your medical team if you are on chronic prednisone or recently received a high dose of prednisone.
- Make sure your physician is familiar with the ICC Treatment guidelines, specifically on vaccinations and flare management. [Guidelines - International Clinical Council \(ICC\) on Fibrodysplasia Ossificans Progressiva \(FOP\) \(iccfop.org\)](#). Notify your physician you plan to do the vaccine, and when.
- On the day of the injection:
 - Your local team may not allow you to take ibuprofen or acetaminophen prior to the injection (this is because they may screen for COVID symptoms first).
 - After you receive your injection, there may be a brief observation period.
 - After that is completed, take ibuprofen (2 to 3 times/day) or acetaminophen (2-3 times/day) following the label instructions, for the next 48 hrs, regardless of your symptoms.
 - Consider local cold compress for 15 to 30 minutes after vaccination
 - Rest and stay hydrated.
 - In the event of a flare, contact your physician for guidance. You may need to do a short course of prednisone, but this needs to be balanced with the immunosuppressive effects of steroids. The usual flare dosing is prednisone 2 mg/kg/day up to 100 mg, for 4 days; your physician may recommend starting at a lower dose, depending on your symptoms.
 - Even if you take the vaccine, you still need to continue physical distancing, wearing masks, and appropriate hand washing

The ICC can't guarantee that these steps will "work" to prevent complications. All medications and treatments have risk, so it is important to discuss your specific situation with your doctor as you decide whether to take the COVID-19 vaccine or not.

Make sure that you complete the full immunization regimen recommended (i.e., do both doses if the vaccine recommends 2 doses)

Discuss with your physician if you should have a booster and if that is appropriate for you.

COVID management is an area of active investigation and rapidly changing. The ICC will update recommendations as more information becomes available.

Important! How does the development of a vaccine change things?

- Recent developments of a vaccine for COVID-19 provides long term hope. However, the impact of the vaccine on the pandemic will take quite some time to manifest. Many types of vaccines are being tested around the world and new variants of SARS-CoV-2 virus are emerging and so this is a rapidly changing field.
- **Vaccines to date are not available for children younger than 5 years, or for anyone by subcutaneous delivery.** These are actively being studied, and will be added to the guidelines once available.
- The exact duration of immunity conferred by the vaccines is unknown but does not seem to be lifelong. Patients who had a vaccine over 6 months ago should consider a booster.
- At this time, the ICC does **not recommend vaccination for children younger than 5 years** due to the lack of safety and efficacy data.

- At this time, the **ICC does not provide recommendations for or against vaccination for patients with FOP older than 5 years of age.** The specific risks and benefits should be discussed with your physician.
- The ICC recommends that **FOP family members and caregivers get vaccinated for SARS-CoV2** if safely available for them.
- Vaccinations can take 2+ weeks to show efficacy, so there is no protection immediately after vaccination. In addition, vaccines do not confer absolute immunity to the SARS-CoV-2 virus, and may not have activity against all forms of the SARS-CoV-2 virus. **Anyone who receives a vaccine should still continue with masking, hand hygiene, and physical distancing.**
- This information is rapidly evolving. Please discuss with your local care providers regarding benefits and risk of any locally approved vaccines.
- It's very important to maintain social distancing and wearing a mask when around members outside your household
- Additional updates will be shared as new information becomes available.

Important! How do the new treatments for COVID infection change things?

- **There are several monoclonal antibodies and new small molecule drugs that are being used to treat patients with active COVID infections.** These are important for supplementing the vaccines.
- Vaccines work by decreasing the risks of infection, and decreasing the severity of the disease if infection occurs. The antibody and small molecule treatments help decrease the severity of COVID after infection occurs.
- Some of these medications may require intramuscular injections.
- **Some of the medications may be useful for preventing infection by SARS-CoV-2 (i.e., prophylaxis).** However, to date these medications appear to be less effective than vaccination, have unknown safety data, and may have limited availability.
- **The antibody and small molecule treatments for COVID are in extremely limited supply.** They may not be available in your area or have strict limitations on who can receive the medication. It is important for each patient with FOP to discuss with their primary care physician about these treatments and to plan ahead.

Important! Recommendations if a patient with FOP or caregiver tests positive for SARS-CoV-2

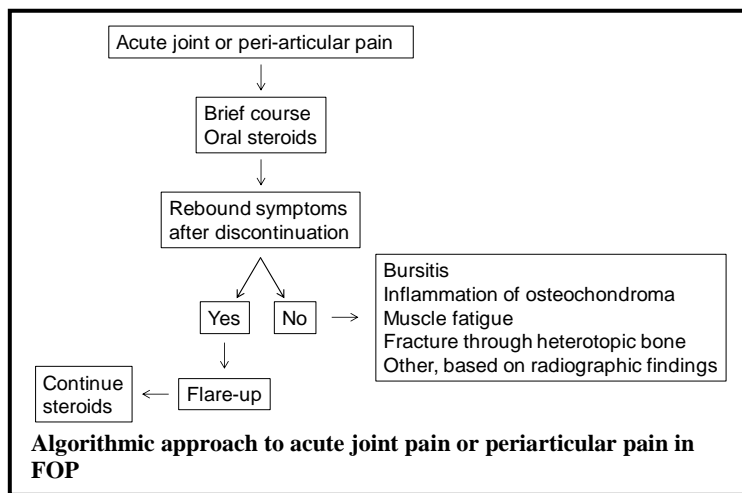
- **Notify your primary care physician to help coordinate care**
- **Follow your local guidelines for isolation/quarantine and the needed durations and procedures.**
- Everyone, including the person with the positive SARS-CoV-2, should wear a mask at all times to avoid transmission.
- **Patients who are negative for SARS-CoV2 but have similar symptoms should be tested for influenza.**
- **Patients should use ibuprofen or acetaminophen, and other over the counter medications, to manage the upper respiratory symptoms.** Discuss with your physicians regarding the appropriate medications and potential medication interactions.
- **New!** Patients with FOP are at high risk of complications with COVID-19 infection and should discuss with their medical team if the use of monoclonal antibodies or anti-retroviral medications would be beneficial, in the event of a SARS-CoV2 infection or high risk exposure
 - o Monoclonal antibodies are given intravenously or intramuscularly and have various different approvals. Some of these antibodies are not effective against certain variants. Those interventions should be started as early as possible and within 5-10 days of symptoms onset. Contact your physician to discuss if these medications are available and beneficial.

- Anti-retroviral medicine (such as Molnupiravir) are pills or injections that have been approved in some countries, including the United States and the United Kingdom, and should be administered within 5 days of symptoms onset and positive COVID test. Right now, in the USA, Molnupiravir is only for adults older than 18 years of age.
- Again, availability and recommendations of the use of these treatments are rapidly changing and country specific. Please consult with your local medical team.

10. Acute & Chronic Pain Management in FOP

General Considerations

According to the IFOPA Patient Registry (Mantick et al., 2018), almost 90% of individuals with FOP have pain complaints. Major causes of acute pain in FOP are musculoskeletal in origin and include flare-ups, transient bursitis, inflammation of osteochondromas, muscle fatigue, and fracture through heterotopic bone. The most important aspect of acute pain management is distinguishing acute pain due to flare-ups versus other etiologies. In a study on the natural history of flare-ups in FOP (Pignolo et al, 2016), the most painful flare-ups occur in the hips and knees.



Based on a recent evaluation of clinical and radiographic findings of acute hip pain in FOP (Kaplan et al., 2018; see section on Differential diagnosis of hip pain), an algorithmic approach to acute joint or periarticular pain may be proposed (Figure). After an initial brief course of steroids to empirically treat for a possible flare-up, observation for rebound symptoms with discontinuation is the critical node for further treatment decisions. The absence of rebound symptoms (i.e., resolution of pain complaints) suggests that the etiology for pain is not related to a flare-up. The presence of continued or worsening symptoms after

discontinuation, however, strongly suggests a flare-up as the likely cause. Plain radiographs of the involved joint can be helpful in the management of acute periarticular pain.

Common causes of chronic pain in FOP include neuropathies, arthritis, generalized chronic pain syndrome in advanced FOP, and other causes of pain such as gastrointestinal pain (see section on gastrointestinal issues). The approach to chronic pain relies on distinguishing between neuropathic and nociceptive etiologies. Neuropathic pain results from damage to or pathology within the nervous system, and can be central or peripheral. In FOP, neuropathies are the major cause of neuropathic pain, related to entrapment syndromes and/or nerve damage. Nociceptive pain is caused by stimuli that threaten or provoke actual tissue damage. In FOP, the major causes of nociceptive pain are musculoskeletal pain (e.g., back pain, myofascial pain syndrome, ankle pain), inflammatory pain, and pain due to mechanical/compressive causes (e.g., visceral pain from expanding HO).

General principles of pain management should be applied to the treatment of chronic pain in FOP. The best approach is to target the etiology of the pain, whenever known, and to make reasonable attempts at understanding at least the type of pain when the etiology is unknown. Optimal outcomes often result from multiple approaches utilized in concert, coordinated via a multidisciplinary team. Some adjuvant, non-pharmacologic modalities can be effective in pain management. Finally, treatment of depression may

provide pain relief separate from correction of the mood disorder.

Treatment of chronic pain is based on neuropathic versus nociceptive components. There is consensus among guidelines on pain management of non-FOP pain syndromes that first-line agents for neuropathic pain include either calcium channel alpha 2-delta ligands (e.g., gabapentin or pregabalin) or tricyclic antidepressants (Gilron et al. 2015; Finnerup et al., 2015). Serotonin norepinephrine uptake inhibitors (SNRIs) are identified as either first or second-line agents (e.g., duloxetine, venlafaxine), although they may be preferred to tricyclic antidepressants. Among the tricyclic antidepressants, side effect profiles appear to favor the secondary amine tricyclics (e.g., nortriptyline and desipramine), although the efficacy is the same for other tricyclics such as amitriptyline. Combination therapy is often required, because less than half of patients with neuropathic pain will respond to a single agent. However, evidence is scant regarding the efficacy and safety of combination treatment. Other second-line agents that may be used include tramadol and other antiepileptics (e.g., carbamazepine or oxcarbazepine). Opioids should be considered a third-line option in FOP, both because of abuse potential and the fact that activation of mast cells and the systemic release of histamine are common side effects of opioids, especially codeine and meperidine (Blunk et al., 2004). Topical agents can be used as adjunctive therapy as appropriate.

The pharmacologic approach to nociceptive pain first begins with an evaluation of risk factors that may contraindicate, limit, or otherwise call attention to the possibility of potential side effects related to the use of non-steroidal anti-inflammatory agents (NSAIDs), the mainstay of treatment (McCormack, 1994; Roelofs et al., 2008). Risk factors include advanced age, renal, hepatic, cardiovascular disease or risk, peptic ulcer, and glucocorticoid use. The latter is directly applicable to FOP, and systemic NSAIDs should not be used concomitantly with steroids. After risk factor evaluation, the next step to nociceptive pain management is an assessment of pain level. Mild to moderate pain can initially be treated with topical agents (see section on Topical Agents) and/or acetaminophen/paracetamol.

Pain not controlled by topical agents or acetaminophen/paracetamol should be managed with NSAIDs plus a proton-pump inhibitor or COX-2 inhibitor with or without acetaminophen/paracetamol. There is controversy over the maximal safe daily dose of acetaminophen, but a 3g to 3.25g daily dose appears to be within a safe maximal range (Heard et al., 2007).

Treatment of moderately severe to severe pain without an inflammatory component or with risk factors for NSAID use should begin with acetaminophen/paracetamol and advanced to tricyclic antidepressants if pain is not adequately controlled. Moderately severe to severe pain with an inflammatory component should be initially treated with NSAIDs plus a proton-pump inhibitor or COX-2 inhibitor with or without acetaminophen/paracetamol. Use of COX-2 inhibitors may decrease the likelihood of gastrointestinal toxicity from NSAIDs (Silverstein et al., 2000). Tricyclic antidepressants can also be used if pain is not adequately controlled. The addition of baclofen or other muscle relaxant may be appropriate for a short period of time if there is a spasmodic component to the pain (see section on Muscle Relaxants). For the reasons stated above, opioids should also be considered a third-line option in FOP for the management of nociceptive pain.

There are many causes of acute and chronic pain in FOP, and each individual must be carefully evaluated before effective treatment can be planned and implemented (Kaplan et al., 2008). Many FOP flare-ups, especially those around the hips and knees, are extremely painful and may require a brief course of well-monitored narcotic analgesia in addition to the use of non-steroidal anti-inflammatory medications, COX-2 inhibitors, and/or oral or IV glucocorticoids. Other types of transient pain

syndromes may be caused by neuropathies resulting from acute flare-ups, transient bursitis, inflammation of osteochondromas, arthritis and muscle fatigue, to mention only a few.

To date, much remains unknown regarding the dynamics of pain and emotional health in FOP during flare-up and also quiescent, non-flare-up disease phases. In order to elucidate the occurrence and effect of pain in FOP, a recent study analyzed patient-reported outcomes measurement information system-based questionnaires completed by 99 patients participating in the international FOP Registry over a 30-month period (Peng et al., 2019). The study observed that while moderate to severe pain (≥ 4 , 0-10 pain scale) was commonly associated with flare-ups (56-67%), surprisingly, 30-55% of patients experienced similar pain levels during non-flare-up states. Furthermore, independent of the flare-up status, the severity of pain in FOP patients was found to be inversely correlated with emotional health, physical health and overall quality-of-life. These findings strongly suggest the need for an improved understanding of pain and emotional health in FOP during flare-up and quiescent periods (Peng et al., 2019).

Those with chronic pain of diffuse musculoskeletal origin may require more specialized pain management programs directed by pain management specialists. Attempts should be made to minimize chronic discomfort, and maximize physical and cognitive function. In most cases, narcotic agents should be avoided to minimize the risk of dependency on these agents. While some may require chronic narcotic analgesics late in the course of their disease process, attempts should be made to monitor this carefully to avoid constipation and respiratory suppression.

Use of alternative or complementary therapies have not been well investigated, but may provide options for reducing systemic pain medication use. Pain neuroscience education may be useful and has been shown to be an effective intervention in all types of pain (Louw et al., 2016). Acupuncture is not recommended due to the potential for tissue trauma.

Other complementary or integrative medicine techniques for pain management should be considered, including the use of biofeedback, therapy pools, therapeutic relaxation, auto-hypnosis, cognitive behavioral therapy, gentle massage/acupressure, and medicinal marijuana (where available). These therapies should be discussed with the treating physician to ensure that there are no adverse interactions with other medications or therapies, or contraindications for an individual patient. Also, procedures such as acupressure and gentle massage need to be performed in a way that does not increase the risks of trauma or inducing a flare. Please discuss with the primary care physician or local pain management team for referrals to a reputable complementary or integrative medicine practitioner.

For those with more chronic pain management issues, a consultation with a pain management specialist may be helpful and is recommended.

Medical Cannabis

Anecdotal use of medical cannabis among patients with FOP is known to occur. This class of drugs is represented by a group of compounds derived from the subspecies of the plant genus *Cannabis* and delivered for potential beneficial effects through inhalation, swallowing, and topical application to skin or buccal mucosa. At the time of this writing, 33 U.S. states and the District of Columbia have programs authorizing cannabis use for specific medical conditions, with varying regulations in other countries. Most states allow its use for a variety of conditions, with those most related to FOP including cachexia/wasting syndrome, muscle spasticity, severe and chronic pain, and severe nausea (Belendiuk et al., 2015). In the U.S., clinicians do not prescribe medical cannabis but only certify for the condition that qualifies patients under state programs.

The National Academies of Sciences, Engineering, and Medicine (NASEM) conducted a comprehensive review on the health effects of cannabis and cannabinoids (NASEM, 2017). The NASEM reported

conclusive or substantial evidence that cannabis or cannabinoids are effective for chronic pain in adults, as anti-emetics, and for improvement of muscle spasticity. Chronic pain is the most common reason individuals use medical cannabis; however, its use needs to be part of a comprehensive symptom management strategy rather than a single modality for pain control, underscoring the importance of continuing other therapies. In this context, it is noteworthy that use of medical cannabis has been associated with significantly lower opioid overdose mortality rates (Bachhuber et al., 2014).

Oral cannabis extracts from naturally occurring phytocannabinoids, orally administered Δ^9 -Tetrahydrocannabinol (THC) and nabiximols (combination THC-cannabidiol [CBD]) are the usually administered forms, but synthetic cannabinoids are also available. Among the different preparations, evidence-based claims regarding clinical efficacy can only be made for smoked or vaporized plant flower, plant-derived oral THC, THC-CBD combinations, and synthetic THC. However, the NASEM noted that there is substantial evidence for an association between cannabis smoking and respiratory disease, motor vehicle collisions (MVCs), lower birth weight of offspring, and schizophrenia or other psychoses (NASEM, 2017). Caution should be exercised when considering medical cannabis for patients under the age of 25 years because brain development continues until this age, and the potential lasting impact of cannabis on cognitive performance is unknown (NASEM, 2017). Also, it is difficult to extrapolate available evidence on medical cannabis given the differences in products obtained from state-run programs due to horticultural techniques, drug extraction methods, and drug delivery modalities.

References

- Bachhuber MA, Saloner B, Cunningham CO, Barry CL. Medical cannabis laws and opioid analgesic overdose mortality in the United States, 1999-2010 [published correction appears in *JAMA Intern Med*. 2014;174(11):1875]. **JAMA Intern Med** 174(10):1668-1673, 2014
- Belendiuk KA, Baldini LL, Bonn-Miller MO. Narrative review of the safety and efficacy of marijuana for the treatment of commonly state-approved medical and psychiatric disorders. **Addict Sci Clin Pract**. 2015; 10:10
- Blunk JA, Schmelz M, Zeck S, Skov P, Likar R, Koppert W. Opioid-induced mast cell activation and vascular responses is not mediated by mu-opioid receptors: an *in vivo* microdialysis study in human skin. **Anesth Analg** 98:364-70, 2004
- Finnerup NB, Attal N, Haroutounian S, et al. Pharmacotherapy for neuropathic pain in adults: a systematic review and meta-analysis. **Lancet Neurol** 14:162, 2015
- Gilron I, Baron R, Jensen T. Neuropathic pain: principles of diagnosis and treatment. **Mayo Clin Proc** 90:532, 2015
- Heard K, Green JL, Bailey JE, et al. A randomized trial to determine the change in alanine aminotransferase during 10 days of paracetamol (acetaminophen) administration in subjects who consume moderate amounts of alcohol. **Aliment Pharmacol Ther** 26:283, 2007
- Kaplan FS, Al Mukaddam M, Pignolo RJ. Acute unilateral hip pain in fibrodysplasia ossificans progressiva (FOP). **Bone** 109:115-119, 2018
- Kaplan FS, Le Merrer M, Glaser DL, Pignolo RJ, Goldsby R, Kitterman JA, Groppe J, Shore EM. Fibrodysplasia ossificans progressiva (FOP). **Best Practice & Research – Clinical Rheumatology** 22: 191-205, 2008

Louw A, Zimney K, Puentedura EJ, Diener I. The efficacy of pain neuroscience education on musculoskeletal pain: A systematic review of the literature. **Physiother Theory Pract** 32:332-355, 2016

Mantick N, Bachman E, Baujat G, Brown M, Collins O, De Cunto C, Delai P, Eekhoff M, Zum Felde R, Grogan DR, Haga N, Hsiao E, Kantanie S, Kaplan F, Keen R, Milosevic J, Morhart R, Pignolo R, Qian X, di Rocco M, Scott C, Sherman A, Wallace M, Williams N, Zhang K, Bogard B. The FOP Connection Registry: Design of an international patient-sponsored registry for Fibrodysplasia Ossificans Progressiva. **Bone** 109:285-290, 2018

McCormack K. Non-steroidal anti-inflammatory drugs and spinal nociceptive processing. **Pain** 59:9, 1994

National Academies of Sciences, Engineering, and Medicine. The Health Effects of Cannabis and Cannabinoids: The Current State of Evidence and Recommendations for Research. Washington, DC: **The National Academies Press**; 2017

Peng K, Cheung K, Lee A, Sieberg C, Borsook D, Upadhyay J. Longitudinal evaluation of pain, flare-Up, and emotional health in fibrodysplasia ossificans progressiva: Analyses of the international FOP registry. **JBMR Plus**. 2019 Mar 1;3(8):e10181. doi: 10.1002/jbm4.10181. eCollection 2019 Aug

Roelofs PD, Deyo RA, Koes BW, et al. Nonsteroidal anti-inflammatory drugs for low back pain: an updated Cochrane review. **Spine** 33:1766, 2008

Silverstein FE, Faich G, Goldstein JL, et al. Gastrointestinal toxicity with celecoxib vs nonsteroidal anti-inflammatory drugs for osteoarthritis and rheumatoid arthritis: the CLASS study: A randomized controlled trial. Celecoxib Long-term Arthritis Safety Study. **JAMA** 284:1247, 2000

11. Differential Diagnosis of Hip Pain in FOP

Flare-ups of the hips are among the most feared and disabling complications of FOP. In a recent study (Kaplan et al, 2018), 25 consecutive individuals with classic FOP who presented with acute unilateral hip pain were evaluated. All 25 individuals were suspected of having a flare-up of the hip based on clinical history and a favorable response to a four-day course of high-dose oral prednisone. Ten individuals (40%) experienced rebound symptoms of pain and/or stiffness within seven days after discontinuation of prednisone and all ten subsequently developed HO or decreased mobility of the affected hip. None of the 14 individuals who experienced sustained relief of symptoms following a course of oral prednisone experienced HO or decreased mobility.

Incidental radiographic findings at the time of presentation were multifactorial and included osteochondromas of the proximal femur (18/25; 72%), degenerative arthritis (17/25; 68%), developmental hip dysplasia (15/25; 60%), previously existing HO (12/25; 48%), intra-articular synovial osteochondromatosis (8/25; 32%) or traumatic fractures through pre-existing heterotopic bone (1/25; 4%). Developmental joint pathology may confound clinical evaluation of hip pain in FOP.

The most useful modality for suspecting an ossification-prone flare-up of the hip was lack of sustained response to a brief course of oral prednisone. Evaluation of soft tissue edema by ultrasound or magnetic resonance imaging showed promise in identifying ossification-prone flare-ups and warrants further analysis in prospective studies; however, plain radiographs were able to reliably identify the likely causes of hip pain unrelated to flare-up.

References

Kaplan FS, Al Mukaddam M, Pignolo RJ. Acute unilateral hip pain in fibrodysplasia ossificans progressiva (FOP). *Bone* 109:115-119, 2018

12. Limb Swelling in FOP

Limb swelling is a common problem in patients who have FOP, yet little is known about this complication. In a published study, detailed medical records were reviewed on a large group of FOP patients to determine the prevalence and natural history of limb swelling (Moriatis et al., 1997). Acute swelling of the limbs occurred in association with flare-ups of the condition in nearly all cases. Acute swelling in the upper limbs was focal and nodular in contrast to acute swelling in the lower limbs, which was more diffuse. The intense angiogenesis and edema seen on histopathologic evaluation of preosseous FOP lesions may play a role in

the pathogenesis of the limb swelling. In addition, proximal lesions in the limb may cause a mechanical blockage of distal limb lymphatic drainage thus exacerbating the swelling.

The acute and often severe limb swelling seen with acute flare-ups of FOP is ascribed to the intense inflammation, angiogenesis and capillary leakage demonstrable in the early FOP lesions. Limb swelling associated with an acute FOP flare-up may grow to extraordinary and alarming size and lead to extravascular compression of nerves and tissue lymphatics. The appearance of such massive acute swelling in the lower limbs can provoke serious considerations of a deep vein thrombosis.

Massive tissue edema may last for 3-6 months after the onset of acute swelling. As fibrocartilaginous tissue matures into chondro-osseous tissue and finally into bone, swelling diminishes. During the following six months, swelling may regress slowly or may persist as chronic limb swelling. As skeletal muscle in the lower limbs is replaced by heterotopic bone, the normal pumping action of the muscle is lost, further exacerbating lymphatic stasis and dependent edema. Progressive ankylosis of the joints continues inexorably and loss of mobility ensues, further increasing venous and lymphatic stasis and dependent edema (Moriatis et al., 1997).

When lymphedema occurs, it is critical to avoid infections and the vicious cycle of lymphedema-cellulitis-lymphedema. Streptococcal cellulitis associated with lymphedema can be aggressive with severe symptoms and morbidity. Prophylactic skin care of the affected limb in preventing ulcers, dermatitis, macerations and tinea pedis is also important in reducing the portal of entry for micro-organisms. Episodes of cellulitis can damage the lymphatic system and predispose to recurrent episodes of cellulitis (Al Niimi & Cox, 2009).

Some patients who have advanced FOP involving the lower limbs have venous stasis in addition to lymphedema. Definitive studies to exclude deep vein thrombosis may be difficult to obtain and interpret due to severe existing deformity and joint ankylosis from previous flare-ups. A decision to anticoagulate a patient should not be made without substantial evidence of deep vein thrombosis. The differential diagnosis of acute upper limb swelling is not nearly as difficult as is the differential diagnosis of acute lower limb swelling in patients who have FOP. Differences in the regional appearance of the FOP lesions cannot be explained at the present time, but may be due to mechanical factors affecting aponeuroses and fascial planes (Moriatis et al., 1997).

Limb swelling is often difficult to treat effectively in patients who have FOP. Non-steroidal anti-inflammatory medications and glucocorticoids generally have not been effective. Support stockings are poorly tolerated by most patients, and elevation of the affected limbs is often impossible because of

ankylosis of the major joints, especially later in the disease process. Where tolerated, support stockings may be helpful. The use of pneumatic compression devices has not been evaluated. Additionally, many have reported anecdotal beneficial effects following treatments at lymphedema clinics.

There are two different types of lymphedema therapy. The Vodder method is most often used in clinics, though the Chikly method, which involves “mapping” the lymph flow and potentially using alternate pathways to reroute the lymph flow, may be more useful for FOP patients for whom HO and/or on-going flare-ups may interfere with the normal channels of lymph flow (Chikly, 2000; Chikly, 2005). Lymphedema clinics can also provide patients with resources to help control lymphedema and are highly recommended.

References

Al Niaimi F, Cox N. Cellulitis and lymphoedema: A vicious cycle. **Journal of Lymphoedema** 4: 38-42, 2009

Chikly, BJ. Manual techniques addressing the lymphatic system: origins and development. **Journal of American Osteopathic Association** 105: 457-464, 2005

Chikly, BJ. Lymph Drainage Therapy (LDT) Manual Lymphatic Mapping and its Clinical Applications to Lymphedema. **The National Lymphedema Network (NLN) Publication** 12(3), 2000

Moriatis JM, Gannon FH, Shore EM, Bilker W, Zasloff M, Kaplan FS. Limb swelling in patients who have fibrodysplasia ossificans progressiva. **Clin Orthop Rel Res** 336: 247-253, 1997

13. Pressure Ulcers in FOP

Skin breakdown and pressure sores are common and troublesome problems in individuals who have advanced FOP. Skin breakdown can occur from increased pressure over normotopic or heterotopic bone.

Pressure ulcers can develop suddenly, progress rapidly, and be difficult to treat (Reddy et al., 2001; Boyko et al., 2018). Preventive measures include:

- Adequate nutrition
 - Daily skin inspections
 - Frequent changes in position
 - Use of a pressure-reducing mattress or bed
 - Use of pressure-reducing dressings or cushions
- If a pressure sore is detected at an early stage when the skin is erythematous but there is no open sore, it will be much easier to treat. Pressure sores involving open wounds require considerably more care.

Follow these suggestions as soon as a problem is identified:

- Change positions frequently and use special cushions designed to relieve pressure.

- Keep the area clean to prevent infection. A stage I wound (no open skin) can be gently washed with water and mild soap. Anything more serious should be washed with saline (salt) solution, which can be obtained from a pharmacy. Avoid using antiseptics such as hydrogen peroxide or iodine which can damage the skin and delay healing.
- Pay special attention to the folded areas of the skin and keep them free of moisture. These areas may be especially problematic for FOP patients when little air can circulate. Keeping these areas dry is very important and simple measures like the use of a thin microfiber washcloth can be helpful.
- Use a special dressing/bandage that protects wounds and helps promote healing. Name brands include Tegaderm and Duoderm. These dressings help keep the wound moist (to promote cell growth) while keeping the surrounding tissue dry. They should not be used on lesions that might be infected.
- Whirlpool baths can be helpful because they help keep the skin clean and naturally remove dead tissue.
- If necessary, damaged tissue can be removed. A wound needs to be free of dead and/or infected tissue to heal properly. There are several ways that this can be done safely, even in FOP.
- Perforating bone may be removed under corticosteroid coverage when absolutely necessary.
- Coordination with a wound care team is important.

References

Boyko TV, Longaker MT, Yang GP. Review of the Current Management of Pressure Ulcers. **Adv Wound Care** 7: 57–67, 2018

Reddy M, Gill SS, Rochon PA. Preventing pressure ulcers: a systemic review. **JAMA** 296: 974-984, 2006

14. Dermatology & FOP

The skin is the largest organ of the human body, and often reflects systemic diseases and their consequences, providing clues to diagnosis. Over many years, doctors and researchers have noticed a connection between FOP and some skin, hair, and nail conditions. Although many aspects of these anecdotal dermatologic findings will be the subjects of future studies, it is possible to state that these conditions can be roughly divided in 4 main types:

- Dermatologic conditions related to a consequence of FOP – immobility, position of the body, poor blood circulation.
- Dermatologic conditions related to the use of drugs (prednisone, NSAIDs, analgesics, and drugs involved in clinical trials).
- Dermatologic conditions related to FOP itself – linked to the genetic mutation and signaling pathway.

- Dermatologic conditions unique to each individual with FOP – genetic, environmental, and/or occupational.

Dermatologic conditions related to a consequence of FOP

A common skin problem that is often seen in individuals with FOP are pressure ulcers. Heterotopic bone can occlude the blood supply to the skin and create an ulcer. It is important to avoid this problem by cushioning vulnerable bony prominences and treating the pressure ulcers as soon as they are found.

Heterotopic bone often crosses joints, creating body folds that are exceedingly difficult to reach and clean – and creating fertile fields for the development of intertriginous lesions, as well as fungal and bacterial infections. Health care professionals must be aware of these possible conditions and minimize the risk of serious infections that can lead to sepsis (Kang et al., 2019).

Heterotopic bone can also lead to compromised circulation as the compression of blood and lymphatic vessels creates poorly oxygenated skin that becomes dry and eczematous. Avoiding hot showers, hot temperatures, and soaps containing lauryl sulfates is recommended. Also, skin moisturizers are recommended. A dermatologist should be consulted about the possible use of steroids and antibiotics (Kang et al., 2019).

Some patients with advanced FOP have reported blisters in the absence of friction or trauma. This may occur from compromised lymphatic circulation. If lymphatic pressure is elevated, tense blisters containing transparent lymphatic fluid may form.

The compression of lymphatic vessels can also be the cause of lymphedema and in extreme cases elephantiasis of the limb with ulcers and verrucous lesions. An ultrasound examination can help to rule out deep venous thrombosis (Moriatis et al., 1997).

Dermatologic conditions related to the use of drugs

Skin, nails, and hair can be affected by the use of certain medications. Many medications can be implicated, but anti-inflammatories and analgesics are the most common culprits. It is not uncommon that FOP patients have skin rashes or hives due to the frequent use of drugs for pain relief or inflammation.

Reactions to drugs can manifest as polymorphic erythema (with lesions on the skin and mucous membranes), fixed pigmented erythema, urticaria (hives), monomorphic acne or dishydrosis, among others (Kang et al., 2019).

The use of prednisone, even for short periods of time, can also cause skin issues that include acne, skin and hair thinning, facial erythema, hirsutism, stria, or impaired wound healing.

Some medications that are being tested in clinical trials also have influences on the skin. Palovarotene can cause dryness of the skin and mucous membranes, retinoid dermatitis, dry lips, and tendency to skin infections, among others. Garetosmab can cause madarosis, acne, folliculitis, furunculus, carbuncles and abscesses.

Dermatologic conditions related to FOP itself – linked to the genetic mutation and signaling pathway

FOP is not just a bone disease. The way in which the genetic mutation affects the various body systems is still largely unknown.

Dermatologic manifestations and their ties to FOP are still being investigated. However, some common features have been anecdotally observed over the years:

Flare-ups. During FOP flare-ups, the skin over the affected area may be tender, erythematous or warm (Pignolo et al., 2016). When bone is already formed, the skin can look glossy and feel hard upon touch, with loss of hair. It is important to avoid confusion with other dermatologic diseases such as scleroderma, among others. Here again, we stress the diagnostic importance of the malformation of the great toes and the development of the progressive heterotopic ossification – signature clinical findings of classic FOP (Blaszczyk et al., 2003).

Scalp nodules. Scalp nodules may appear during childhood. They usually disappear spontaneously (McFarland et al., 1984).

Hair loss. Hair loss has occasionally been reported as a symptom of FOP, especially with severe FOP variants. Patients also report other hair-related issues (sparse eyebrows, less and lighter body hair. etc.) These additional issues may also be under-reported symptoms of FOP (Pignolo et al., 2020).

Hypersensitivity to insect bites. This may be related to increased systemic mast cell reactivity in FOP (Pignolo et al., 2020).

Rare skin tumors. Merkel cell carcinoma (rare, aggressive, malignant primary cutaneous neuroendocrine tumor) has been noted rarely in some FOP patients – possibly related to lifelong corticosteroid use or sun exposure (Kang et al., 2019)

Other skin abnormalities. Other skin abnormalities ranging from skin discoloration to immune-related conditions such as seborrheic dermatitis have been noted in some FOP patients.

Clearly, there is a tremendous need to evaluate these dermatologic issues in the wider FOP community in order to determine the prevalence and risk of skin-related conditions in FOP.

Dermatologic conditions unique to each individual with FOP – genetic, environmental, and/or occupational

Dermatological evaluation of a patient with FOP needs to be careful and comprehensive. Although the items above are often be noted in FOP, their relative prevalence is unknown.

References

Blaszczyk M, Majewski S, Brzezinska-Wcislo L, Jablonska S. Fibrodysplasia ossificans progressiva. **Eur J Dermatol** 13(3):234-237, 2003

Kang S, Masayuki A, Bruckner AL, Enk AH, Margolis DJ, McMichael AJ. **Fitzpatrick's Dermatology**, 9e Orringer 2019

McFarland GS, Robinowitz B, Say B. Fibrodysplasia ossificans progressive presenting as fibrous scalp nodules. **Cleve Clin Q** 51:549-552, 1984

Moriatis JM, Gannon FH, Shore EM, Bilker W, Zasloff MA, Kaplan FS. Limb swelling in patients who

have fibrodysplasia ossificans progressiva. **Clin Orthop Rel Res** 336: 247-253, 1997

Pignolo RJ, Bedford-Gay C, Liljestrom M, Durbin-Johnson BP, Shore EM, Rocke DM, Kaplan FS. The natural history of flare-ups in fibrodysplasia ossificans progressiva: a comprehensive global assessment. **J Bone Miner Res** 31:650-656, 2016

Pignolo RJ, Wang H, Kaplan FS. Fibrodysplasia Ossificans Progressiva (FOP): A segmental progeroid syndrome. **Front Endocrinol (Lausanne)**. 2020 Jan 10;10:908. doi:10.3389/fendo.2019.00908. eCollection 2019

15. Fractures & Dislocations in FOP

Individuals with FOP are at increased risk of fractures of both the normotopic and heterotopic skeleton due to the increased risk of falls, immobility and prednisone use. In FOP, fractures can occur in both normotopic and heterotopic bone (Pignolo et al., 2016). Fractures of heterotopic bone occur commonly and heal rapidly. Elevation, rest, splinting, and local application of ice are often helpful in controlling pain and swelling, and may be supplemented by acute use of narcotic analgesia, if needed. Fractures of normotopic bone need to be carefully evaluated, as in any patient. Closed reduction and splinting is sufficient for most fractures. Open reduction or internal fixation is rarely warranted and can lead to rapid onset of HO. Healing may be delayed in osteoporotic bone. Nonunion has not been reported in FOP (Einhorn & Kaplan, 1994).

The absence of temporomandibular joint (TMJ) flare-ups and the suddenness of closure suggests a mechanical problem such as acute subluxation or dislocation of the jaw – rather than a flare-up. This is relatively easy to rule out with a CT scan of the TMJ. The key historical clue to subluxation of the TMJ in FOP is the absence of flare-up and the suddenness of closure. It is often painful, but may be less so in FOP. We now know that many FOP joints are malformed to various degrees - not just the great toe (Towler et al., 2020). The developmental anomalies of the jaw have received very little attention.

The TMJ in FOP patients is prone to develop problems. This may be due to developmental abnormalities as mentioned above. The TMJ in FOP does not form normally. The mandibular condyles are often flat and the menisci (similar to the knee) are often malformed. We rarely ask FOP patients to open their mouth maximally, but if we did, we would see that this does not occur normally. We assign a CAJIS of zero if there is good functional opening (but not maximal because we don't test it).

If the TMJ is not subluxed or dislocated and if it is fused, do not try to force it open. Most patients do well with multiple small meals and puréed foods - not ideal - but bearable. Very few need a naso-gastric tube, but those who do tend to tolerate it well. The overbite of FOP can often help with access to eating. If necessary, back teeth can be removed to help with dental access, eating, and fear of vomiting.

References

Einhorn TA, Kaplan FS. Traumatic fractures of heterotopic bone in patients who have fibrodysplasia ossificans progressiva. **Clin Orthop Rel Res** 308: 173-177, 1994

Pignolo RJ, Bedford-Gay C, Liljestrom M, Durbin-Johnson BP, Shore EM, Rocke DM, Kaplan FS. The natural history of flare-ups in fibrodysplasia ossificans progressiva: a comprehensive global assessment. **J**

Towler OW, Shore EM, Kaplan FS. Skeletal malformations and developmental arthropathy in individuals who have fibrodysplasia ossificans progressiva. **Bone**. 2020 Jan; 130:115116. doi: 10.1016/j.bone.2019.115116. Epub 2019 Oct 23

16. Nutrition, Calcium & Vitamin D Guidelines in FOP

Patients with FOP are at high risk of nutritional and vitamin deficiencies due to multiple factors, including but not limited to gastrointestinal issues, ankylosed jaw, nausea and poor appetite (Mantick et al., 2018).

We know of several FOP patients diagnosed with SMA (superior mesenteric artery) syndrome. SMA is a rare life-threatening condition that causes bowel obstruction due to mechanical compression of the third portion of the duodenum by the superior mesenteric artery. SMA has been associated with low BMI and scoliosis surgery (Smith et al., 2009). Weight gain can help with resolution of the bowel obstruction.

Adequate nutrition is especially important in FOP patients to prevent severe weight loss, SMA syndrome and pressure ulcers. For patients with an ankylosed jaw, we recommend referral to a nutritionist; in extenuating situations, patients might need a feeding tube. Ideal weight will be difficult to determine due to inaccurate height measurements and BMI calculation, but we recommend monitoring weight and addressing unintentional weight loss (>5% of weight over 6-12 months) as soon as it is noted (Wong, 2014).

FOP patients can also have vitamin deficiencies, including vitamin D deficiency, especially if they spend most of their time indoors. Calcium intake could also be suboptimal due to the misconception that it could further worsen heterotopic ossification.

We recommend that patients not limit their calcium intake and obtain the recommended dietary allowance (RDA) as per Institute of Medicine 2011 guidelines, which would be 1,000 mg of elemental calcium daily for adults, age 18-50 years old. We recommend that calcium intake be obtained using diet (example milk, cheese, yoghurt or food items fortified with calcium like orange juice and almond milk) and limit calcium supplements to no more than 500 mg daily. Excessive calcium intake, especially in the form of supplements, can increase risk of kidney stones.

We recommend that patients also obtain the RDA for vitamin D as per the Institute of Medicine 2011 guidelines, which would be 600 units of Vitamin D3 daily for adults, age 18-50 years old. We recommend measuring serum 25-OH-vitamin D and repleting as needed to maintain a level >20-30 ng/dl. Low 25-OH-vitamin D levels in the serum are associated with osteomalacia/rickets that could lead to increased risk of normotopic bone fracture. In addition, low vitamin D levels increase the risk of hypocalcemia after administration of intravenous bisphosphonates.

References

Mantick N, Bachman E, Baujat G, Brown M, Collins O, De Cunto C, Delai P, Eekhoff M, Zum Felde R, Grogan DR, Haga N, Hsiao E, Kantanie S, Kaplan F, Keen R, Milosevic J, Morhart R, Pignolo R, Qian X, Di Rocco M, Scott C, Sherman A, Wallace M, Williams N, Zhang K, Bogard B. The FOP connection registry: Design of an international patient-sponsored registry for Fibrodysplasia Ossificans Progressiva. **Bone** 109:285-290, 2018

Smith B, Hakim-Zargar M, Thomson J. Low body mass index: a risk factor for superior mesenteric artery

syndrome in adolescents undergoing spinal fusion for scoliosis. **J Spinal Disord Tech** 22(2):144-8, 2009
Wong CJ. Involuntary weight loss. **Med Clin North Am** 98(3):625-43, 2014

Institute of Medicine 2011 Dietary reference intakes for calcium and vitamin D. Washington, DC: **The National Academies Press**

17. Preventive Oral Healthcare in FOP

Individuals with FOP have developmental anomalies of the temporomandibular joints (TMJs) (Connor & Evans, 1982; Renton et al., 1982; Carvalho et al., 2011). Spontaneous or post-traumatic ankylosis of the TMJs is common and leads to severe disability with resultant difficulties in eating and poor oral hygiene. Great care must be taken not to provoke flare-ups of the TMJ (Luchetti et al., 1996).

Managing the risk of getting any form of oral disease is essential in patients with FOP, especially during childhood years (Young et al., 2007). Preventing development of caries or periodontal disease is crucial to prevent long-term dental and oral complications in patients with FOP.

Fluoridation of water is suggested for all patients who have FOP. The use of high dose fluoride toothpaste (once an individual is able to spit) is recommended along with use of fluoride gels and rinses to help prevent the need for restorative dental care (Hujoel et al., 2018). Children who are unable to spit can use a rice size grain of normal fluoridated toothpaste.

Frequent flossing and brushing are necessary in patients with FOP, as in anyone, but may be difficult due to limited jaw opening as FOP progresses. Ultrasonic toothbrushes with small heads, water picks and floss wands may also help with dental hygiene.

Patients with FOP who have sufficient mouth opening can be treated with normal dental instruments as in unaffected individuals, but great care must be exercised to prevent overstretching of the TMJs during dental procedures. In patients who have ankylosed TMJs, professional instrumentation and special toothbrushes may be helpful, but are often limited to use on the buccal surfaces. Antimicrobial and fluoride rinses may be the only method to reach the lingual and palatal surfaces (Nussbaum et al., 2005).

For patients who have frank cavitation use of 38% Silver Diamine Fluoride is recommended as a non-surgical treatment approach. Use of sealants in both primary and permanent dentition is highly recommended (Slayton et al., 2018).

For FOP patients with frank cavitation requiring **minor** restorative procedures that can be performed in a dental office using interligamentary anaesthesia or lasers (but **never** mandibular blocks), treatment can be accomplished without the use of pre-operative prednisone. This approach requires pre-operative assessment of maximum mouth opening and placement of a molt mouth prop 3-4 mm less than the maximum opening. Frequent intermissions are beneficial in order to limit stress and injury to soft tissue. Multiple appointments are possible. However, two-week intervals between appointments are suggested.

In patients who have difficulty maintaining oral hygiene or who have gingivitis, chlorhexidine rinses are encouraged. If chlorhexidine is used, it is normally used once daily for 6 weeks and then once daily for one week a month. Long time use of chlorhexidene can result in staining of teeth.

Patients with a high risk of dental caries or difficulty in maintaining good oral hygiene may request that their dentist professionally apply fluoride varnish or a bio-erodible and fluoride resin. There is good evidence that these modalities are effective in inhibiting tooth demineralization (Donly, 2003; Lin et al., 2009; Pitts & Zero, 2016; Slayton et al., 2018). A minimum three months' professional follow-up for these patients is suggested. For patients who have early stages of interproximal lesion development use of a resin infiltration technique plus the use of a fluoride varnish is suggested (Slayton et al., 2018).

Saliva testing is highly recommended for patients with FOP. If a patient has inadequate resting and stimulated saliva flow habitual rinsing with water after any food intake is helpful. Saliva substitutes may also be helpful. For patients who may have a low pH or inability to buffer use of MI Paste – Amorphous Casein Phosphate (ACP) (Pitts & Zero, 2016) may be beneficial as will use of xylitol containing gum and or rinses.

Any activity that can minimize the risk of oral health degradation should be implemented. The focus on this section is the pharmacologic treatment of disease rather than surgical. This is especially important in someone with FOP where doing invasive dental treatment can trigger flare-ups.

The following is a list of such suggestions:

Pediatric patients under 3 years of age:

- First visit to an oral health professional - by latest one year of age.
- Begin oral sanative cleaning after each breast or bottle feeding.
- Use rice size grain of fluoridated toothpaste especially if living in a non-fluoridated area.
- Minimize use of soft cariogenic foods. Sugar is ubiquitous and present in many foods commonly given to children. Yoghurt is a good example of a food that may contain an excess of sugar.
- Fluoride varnish suggested twice annually for children at high risk

Pediatric patients over 3 years of age:

- Assess risk of development of oral disease and if high risk 3 monthly professional appointments suggested. If this is not possible, begin use of high dose fluoride toothpaste (rice size grain) and frequent daily brushing and flossing.

Pediatric patients over 5 years of age (who can spit):

- Begin use of fluoride toothpaste – if high risk, use high dose fluoride toothpaste
- Continue to monitor and direct diet that is low in sugar
- Most children do not have the ability to floss effectively until 10-11 years of age and would benefit from assistance. (Floss aids can be used. However, parent should be aware of cross contamination and be sure to rinse a floss wand after flossing each tooth area)
- Monitor nasal or mouth breathing – snoring or grinding. Mouth breathing can cause altered oral facial development and increase risk for oral disease
- Patients with normal mouth opening can be treated with normal dental instruments however, care should be taken to prevent overstretching of the TMJ and musculature. Trauma and anoxia are known triggers for FOP episodes
- Orthodontics – (see section on orthodontics)

Adolescents and Adults:

- In patients who have normal mouth opening and are at low risk – regular care, brushing, flossing, fluoridated toothpaste and dietary monitoring are suggested. Bi-annual professional visits should be sufficient
- Orthodontics (see section on orthodontics)
- Any patient who is at high risk for oral disease should be seen at least every three months, if possible.
- For patients with any decrease in mouth opening, jaw dysfunction, or difficulty in maintaining good oral hygiene, the following are recommended:
 - High dose fluoride toothpaste
 - Saliva testing and appropriate intervention based on results
 - Silver Diamine fluoride 38% application on any beginning lesion (cavity)
 - Fluoride, xylitol rinses
 - Monitor and minimize sugar intake
 - Use of chlorhexidine rinses or varnish
 - Fluoride varnishes
 - For minimal interproximal lesions – resin infiltration techniques and fluoride varnish
 - Brushing and flossing aids. Electric toothbrushes with small heads, water pics and floss wands are examples.
 - CMP (MI paste)
 - Xylitol containing gum

References

Carvalho DR, Farage L, Martins BJ, Speck-Martins CE, Craniofacial findings in fibrodysplasia ossificans progressiva: computerized tomography evaluation. **Oral Surg Oral Med Oral Pathol Oral Radiol Endod** 111:499-502, 2011

Connor JM & Evans DA. Extra-articular ankylosis in fibrodysplasia ossificans progressiva. **Br J Oral Surg** 20: 117-121, 1982

Donly KJ. Fluoride Varnishes. **J Calif Dental Assoc** 31: 217-219, 2003

Hujoel PP, Hujoel MLA, Kotsakis GA. Personal oral hygiene and dental caries: A systematic review of randomised controlled trials. **Gerodontology** May, 2018 [Epub ahead of print]

Lin R, Hildebrand T, Donly KJ. *In vitro* remineralization associated with a bioerodible fluoridated resin and a fluoride varnish. **Am J Dentist** 22: 203-205, 2009

Luchetti W, Cohen RB, Hahn GV, Rocke DM, Helpin M, Zasloff M, Kaplan FS. Severe restriction in jaw movement after route injection of local anesthetic in patients who have fibrodysplasia ossificans progressiva. **Oral Surg Oral Med Oral Pathol Oral Radiol Endod** 81: 21-25, 1996

Nussbaum BL. Dental care for patients who are unable to open their mouths. **Dental Clin North Am** 53: 323-328, 2009

Nussbaum BL, Grunwald Z, Kaplan FS. Oral and dental healthcare and anesthesia for persons with fibrodysplasia ossificans progressiva. **Clin Rev Bone Miner Metab** 3: 239-242, 2005

Pitts N, Zero D. White paper on Dental Caries Prevention and Management: fdiworldental.org/media/93783/2016-fdi_cpp-white_paper.pdf, 2016

Renton P, Parkin SF, Stamp TC. Abnormal temporomandibular joints in fibrodysplasia ossificans progressiva. **Br J Oral Surg** 230: 31-38, 1982

Slayton RL, Urquhart O, Araujo MWB, Fontana M, Guzmán-Armstrong S, Nascimento MM, Nový BB, Tinanoff N, Weyant RJ, Wolff MS, Young DA, Zero DT, Tampi MP, Pilcher L, Banfield L, Carrasco-Labra A. Evidence -based clinical practice guideline on non-restorative treatments for carious lesions. A report from the American Dental Association. **JADA** 149: 837-849, 2018

Young JM, Diecidue RJ, Nussbaum BL. Oral management in a patient with fibrodysplasia ossificans progressiva. **Spec Care Dentist** 27: 101-104, 2007

18. Orthodontics & FOP

Most people seek orthodontic care for aesthetic and functional reasons. For the FOP population, self-image is as important as in the general population. Orthodontic therapy can be safely performed on patients with FOP who have normal or nearly normal oral opening (Luchetti et al., 1996).

Patients who have FOP often develop mandibular hypoplasia with a maxillary overbite and, therefore, orthodontic therapy may be considered (Hammond et al., 2012). However, many patients find that the overbite provides a means of access for eating as well as for oral and dental hygiene. Posterior and anterior dental cross-bites can have an effect on the TMJs and should be corrected. For children with functional TMJs and with anterior open bites that are less than 15 mms, orthodontics is not recommended as the overbite will facilitate nutrition and subsequent dental care if the TMJ does eventually ankylose.

When orthodontic care is considered, brief appointment times should be used to lessen stress on the TMJs.

The use of non-extraction therapy is also recommended. To prevent the need for extractions in FOP patients, it may be advisable to align the anterior segments for aesthetics, leaving posterior dental crowding untreated. Crowded posterior teeth may be a better alternative than the risks of flare-up and TMJ ankylosis that can accompany an extraction (Levy et al., 1999). Use of Invisalign orthodontics may be advantageous as forces generated are far less than with traditional orthodontics and daily maintenance of oral health is considerably easier.

References

Hammond P, Suttie M, Hennekam RC, Allanson J, Shore EM, Kaplan FS. The face signature of fibrodysplasia ossificans progressiva. **Am J Med Genet** 158A: 1368-1380, 2012

Levy CE, Berner TF, Bendixen R. Rehabilitation for individuals with fibrodysplasia ossificans progressiva. **Clin Rev Bone Miner Metab** 3: 251-256, 2005

Luchetti W, Cohen RB, Hahn GV, Rocke DM, Helpin M, Zasloff M, Kaplan FS. Severe restriction in jaw movement after route injection of local anesthetic in patients who have fibrodysplasia ossificans progressiva. **Oral Surg Oral Med Oral Pathol Oral Radiol Endod** 81: 21-25, 1996

19. Submandibular Flare-ups in FOP

Submandibular flare-ups are among the most concerning of all flare-ups due to their potential for causing difficulties in breathing and swallowing. Rarely, however, does jaw movement become affected by flare-ups isolated to this region. Due to their significance for vital functions, submandibular flare-ups warrant special attention (Janoff et al., 1996; Leavitt et al., 2009).

A comprehensive study of submandibular swelling in patients with FOP was undertaken by Janoff et al. and published in 1996. Twelve (11%) of 107 patients who were studied had submandibular HO that was mistaken initially in seven of the patients for mumps, angioneurotic edema, abscess, mononucleosis, or neoplasm. Two male patients and ten female patients ranging in age from 6-47 years (mean: 21 years) were studied. Ten patients survived following assiduous precautionary measures. One patient who required emergency tracheostomy and ventilatory support also survived. Another patient died of inanition from chronic swallowing difficulty. An effective treatment program includes early identification of the submandibular flare-up, nutritional support, and glucocorticoid therapy. Submandibular swelling in patients who have FOP can be a medical emergency and requires intensive precautionary measures to avoid catastrophic clinical deterioration. These measures include avoidance of lesional manipulation, airway monitoring, and aspiration precautions. Submandibular swelling should be recognized as a variable feature of FOP with important potential additional clinical consequences (Janoff et al., 1996).

In an isolated case report of submandibular swelling in a patient with FOP (Leavitt et al., 2009) notes that submandibular flare-ups can be troublesome and endanger the airway or swallowing. The authors note that patients with FOP often have limited jaw movement and associated dental problems and that dental professionals often misdiagnose FOP patients with submandibular flare-ups as having dental abscesses or odontogenic infection. Making matters worse, any manipulation of the soft tissues of the mouth, or the head, or neck will hasten inflammation and worsen the clinical problems of heterotopic bone formation and thus also worsen the FOP flare-up in the submandibular region.

Patients with submandibular flare-ups of FOP must be properly diagnosed so that intensive precautionary measures to avoid catastrophic clinical deterioration can be instituted. An important challenge in the care of patients with a submandibular flare-up of FOP is to effectively manage the acute symptoms and associated discomfort while avoiding meddlesome intervention that will likely exact the lesion.

On the basis of our extensive clinical experience, we recommend the following:

1. All physicians who treat patients with FOP should be aware that acute submandibular swelling may be a manifestation of the disease at any age and can occur during childhood in patients with rapid disease progression.
2. Diagnosis of FOP should be communicated to the attending physician so that the acute submandibular lesion can be managed in the context of the patient's underlying disease.
3. Manipulation of acute lesions must be avoided because even minor trauma can lead to catastrophic exacerbation with airway compromise.

4. Patients having an acute submandibular flare-up should sleep with their head elevated, if possible to decrease the risk of airway obstruction.
5. Patients with an acute submandibular flare-up should be monitored closely during the acute swelling phase and should be hospitalized immediately in the event of pending obstruction of the airway.
6. Food should be pureed or semi-solid. Clear liquids often provoke choking episodes during submandibular flare-ups as the involved muscles are those that move the tongue at the floor of the mouth.
7. Patients should be encouraged to eat frequently to minimize weight loss.
8. Additional high calorie food supplements should also be considered.
9. Assiduous precautions should be undertaken to prevent food aspiration.
10. High dose oral glucocorticoids should be considered in the very early treatment of acute submandibular flare-ups. The glucocorticoid of choice is prednisone and the dose is 2 mg/kg of bodyweight (up to 100 mg) taken per oral once daily for four days at the earliest sign of an acute flare-up. While these flare-ups do not last longer than flare-ups at other locations, the functional consequences of flare-ups in the submandibular region may warrant a longer glucocorticoid treatment course or a second course of steroids if severe soft tissue swelling recurs after cessation of steroid use. If a second four-day course of high dose glucocorticoids is used, the steroids should be tapered slowly over the next two to three weeks. Following discontinuation of the glucocorticoid therapy, non-steroidal anti-inflammatory medications or a cox-2 inhibitor can be considered for the next 6-8 weeks.

References

Janoff, HB, Zasloff MA, Kaplan FS. Submandibular swelling in patients with fibrodysplasia ossificans progressiva. **Otolaryngol Head Neck Surg** 114: 599-604, 1996.

Leavitt BD, Teeples TJ, Viozzi CF. Submandibular space swelling in a patient with fibrodysplasia ossificans progressiva: a diagnostic dilemma. **J Oral Maxillofac Surg** 67: 668-673, 2009.

20. Dental Anesthesia in FOP

Patients with FOP have limited options for dental anesthesia. Mandibular blocks are forbidden as they will lead to ossification of the pterygoid muscles and rapid ankylosis of the TMJ (Luchetti et al., 1996). Infiltration anesthesia is difficult in the mandibular posterior molar areas of permanent teeth. Successful anesthesia in mandibular primary teeth can be achieved by infiltration through the dental pulp. Use of a hard tissue laser can preclude the use of anesthesia especially in small lesions.

Interligamentary infiltration may be helpful, if performed carefully. However, in some patients, this type of local anesthesia may not be possible. General anesthesia (GA) may be needed for dental care in patients with FOP (Nussbaum et al., 1996; Nussbaum et al., 2005).

Cervical spine fusion, ankylosis of the TMJ, thoracic insufficiency syndrome, restrictive chest wall disease, and sensitivity to oral trauma complicate airway management and anesthesia and pose life-threatening risks in individuals with FOP.

A retrospective chart review was conducted at one institution of patients with FOP who underwent GA for treatment of complex dental procedures (Kilmartin et al., 2014).

Thirty patients underwent 42 general anesthetics. GA was induced most commonly after the airway was secured by an awake fiberoptic intubation. GA can be administered safely to patients with FOP for dental procedures with attention to airway management and perioperative care using a multidisciplinary approach. An awake nasal fiberoptic intubation should be considered the first choice for airway management. Most patients can be discharged home on the same day as their dental procedure.

This large case series demonstrates that GA for dental procedures can be safely accomplished in patients with FOP using a multidisciplinary approach. Because of the difficult airway management reports in the literature and the routine use of numerous medical specialties, we recommend that patients with FOP are cared for at an institution where a multidisciplinary approach is possible.

An **anesthesiologist** should evaluate the patient preoperatively, preferably before the day of the procedure. An **otolaryngologist** should be immediately available during the procedure to assist with airway management and perform an emergency tracheostomy if needed. A **dentist** and an **oral maxillofacial surgeon** should be involved in each case so that a comprehensive oral rehabilitation with tooth extractions can occur under one GA setting, which is safer and more convenient for the patient.

Other medical practitioners, such as **pediatricians, family medicine physicians, cardiologists, pulmonologists** and **intensivists**, may be required.

An awake nasal fiberoptic intubation should be considered the first choice for airway management. There are several reasons for choosing GA with an endotracheal tube in this case series.

First, routine injections of local anesthetic for dental procedures, especially mandibular blocks, should be avoided because they can precipitate flare-ups and cause fusion of the TMJ.

Second, oral access can be difficult if a patient has decreased mouth opening. If a tooth fragment were dropped in the mouth of an unintubated patient with a fused jaw, it could be impossible to retrieve. An endotracheal tube provides needed airway protection.

Third, the dentist and the oral and maxillofacial surgeon may need Trendelenburg positioning for long periods of time. This positioning may cause patient discomfort and result in respiratory compromise, especially in patients with preexisting pulmonary disease.

Positioning consideration is essential; patients' bodies are often fused in a rigid position. All pressure points must be padded, and the neck supported. If a patient's cervical spine is fused in flexion, a steep Trendelenburg positioning is often needed for adequate dental exposure. Positioning considerations for Trendelenburg include padding the patients' shoulders and securing the patients to the bed to ensure that their bodies do not shift on the operating room table.

We recommend the administration of perioperative corticosteroids to prevent and mitigate flare-ups. A 4-day perioperative corticosteroid course should be administered according to the current guidelines and begin before the start of the procedure.

In summary, a multidisciplinary approach to the perioperative management of patients with FOP should be the standard of care. Patients should be pretreated with corticosteroids and carefully positioned for surgery. GA can be safely administered to FOP patients for dental procedures; an awake nasal fiberoptic intubation is suggested as the first choice for airway management. Most patients can be discharged home on the same day as their dental procedure.

For pre-op consultation on GA for FOP patients, please contact:

Zvi Grunwald, M.D.

The James D. Wentzler Professor and Chairman Emeritus
Department of Anesthesiology
Thomas Jefferson University and Hospitals
111 South 11th Street, Suite G-8490
Philadelphia, PA 19107, USA
Tel: 215-955-6161
Cell: 215-206-7362
Fax: 215-923-5507
Email: zvi.grunwald@jefferson.edu

References

Kilmartin E, Grunwald Z, Kaplan FS, Nussbaum BL. General anesthesia for dental procedures in patients with fibrodysplasia ossificans progressiva: a review of 42 cases in 30 patients. **Anesth Analg** 118: 298-301, 2014

Luchetti W, Cohen RB, Hahn GV, Rocke DM, Helpin M, Zasloff M, Kaplan FS. Severe restriction in jaw movement after route injection of local anesthetic in patients who have fibrodysplasia ossificans progressiva. **Oral Surg Oral Med Oral Pathol Oral Radiol Endod** 81: 21-25, 1996

Nussbaum BL, Grunwald Z, Kaplan FS. Oral and dental healthcare and anesthesia for persons with fibrodysplasia ossificans progressiva. **Clin Rev Bone Miner Metab** 3: 239-242, 2005

Nussbaum BL, O'Hara, I, Kaplan FS. Fibrodysplasia ossificans progressiva: report of a case with guidelines for pediatric dental and anesthetic management. **ASDC J Dent Child** 63: 448-450, 1996

21. General Anesthesia in FOP

General Considerations

Cervical spine fusion, ankylosis of the TMJ, thoracic insufficiency syndrome, restrictive chest wall disease, and sensitivity to oral trauma complicate airway management and anesthesia and pose life-threatening risks in individuals with FOP. Due to the challenges of airway management, general anesthesia (GA) is needed for most procedures in FOP patients and is an exceedingly complex issue (Kilmartin et al., 2014)

GA can be administered safely to patients with FOP with attention to airway management and perioperative care using a multidisciplinary approach. An awake nasal fiberoptic intubation should be considered the first choice for airway management.

Because of the difficult airway management reports in the literature and the routine use of numerous medical specialties, we recommend that patients with FOP are cared for at an institution where a multidisciplinary approach is possible.

An anesthesiologist should evaluate the patient preoperatively, preferably before the day of the procedure. An otolaryngologist should be immediately available during the procedure to assist with airway management and perform an emergency tracheostomy if needed. Other medical practitioners, such as pediatricians, family medicine physicians, cardiologists, pulmonologists and intensivists, may be required.

In summary, a multidisciplinary approach to the perioperative management of patients with FOP must be the standard of care. Patients should be pretreated with corticosteroids and carefully positioned for surgery. An awake nasal fiberoptic intubation is suggested as the first choice for airway management. Even minor procedures should be scheduled to a major hospital setting, however same day discharged may be considered for individual patients. If postoperative admission is considered follow up should be assigned to an intensive care setting.

For pre-op consultation on GA for FOP patients, please contact:

Zvi Grunwald, M.D.

The James D. Wentzler Professor and Chairman Emeritus

Department of Anesthesiology

Thomas Jefferson University and Hospitals

111 South 11th Street, Suite G-8490

Philadelphia, PA 19107, USA

Tel: 215-955-6161:

Cell: 215-206-7362

Fax: 215-923-5507

Email: zvi.grunwald@jefferson.edu

Pre-operative preparation:

A preoperative visit and meeting with the anesthesiologist prior to the date of surgery is crucial for conducting a safe and smooth general anesthesia course. The anesthesiologist should become familiar with FOP, learn about the extent of the disease affecting the individual patient, and carefully plan the perioperative anesthesia care.

In the case of a patient presenting with advanced disease, thoracic insufficiency syndrome, significant ankylosis of multiple joints, and/or limited mobility and co-morbidities, the anesthesiologist should plan to assemble a multidisciplinary team consisting at least of an anesthesiologist and a surgeon experienced in emergency airway management. Sharing the anesthesia plan with the patient and the family is useful to diffuse apprehension and foster cooperation on the day of surgery.

The special care and the skills required by the anesthesiologist to treat an FOP patient may not be available at peripheral locations or community hospitals. In these situations, the referring physician, the patient, and the family should seek referral to a major medical center with practitioners who are skilled in the care of FOP patients and the anesthesiologist can perform nasal fiberoptic intubation of the trachea.

We recommend the administration of perioperative corticosteroids to prevent and mitigate flare-ups associated with most surgical procedures. A four-day postoperative corticosteroid course should be administered according to the current guidelines and begin on the day of surgery - before the start of the procedure.

Intra-operative management:

Positioning. Positioning consideration is essential as patients' bodies are often fused in a rigid position. All pressure points must be padded, and the neck supported. Positioning considerations for Trendelenburg include padding the patients' shoulders and securing the patients to the operating room table to ensure that their bodies do not shift during the surgical procedure. **Extra padding will help minimize soft tissue trauma during the surgical procedure. The operating room table should be adjusted according to patient's needs.**

Monitoring: Routine monitoring is required for most surgical procedures (ECG, non-invasive blood pressure, pulse oximetry, end-tidal CO₂, and temperature). Significant co-morbidities, lengthy surgical procedures, or a compromised cardio-respiratory system may require additional monitors. In patients whose upper limbs are ankylosed in adduction and flexion, the application of a blood pressure cuff may be difficult or impossible. The cuff may be applied on the lower extremity. A thin layer of padding under the cuff may reduce the impact of the frequent inflations of the cuff on the extremity.

Intravenous access: Careful venipuncture and short-term application of a tourniquet are usually benign. Indwelling intravenous or arterial catheters may rarely lead to the formation of an ossified tract at the site of insertion. Therefore, the smallest intravenous catheter appropriate for the procedure should be selected for insertion.

General anesthesia and sedation: The administration of general anesthesia and the maintenance of a patent airway are particularly challenging matters in patients who have FOP, and should be planned with exacting care. Guidelines for general anesthesia have been reported (Kilmartin et al., 2014).

Physicians and patients may be tempted to use sedation techniques and perform minor surgical procedures at an office-based or out-patient facility. The risks of catastrophic airway emergencies far outweigh the potential benefits of this option. Procedures should be performed only at facilities equipped with the skills and support systems necessary for a safe outcome. For patients with advanced disease, it is recommended that even minor procedures (colonoscopies, dental procedures)

be performed at a major medical center under general anesthesia with a secured airway by nasal fiberoptic endotracheal intubation.

Patients who can open the mouth: In patients who are able to open the mouth, it is imperative to avoid over-stretching the TMJ during direct laryngoscopy. Careful positioning of the patient and the head, maintenance of a sniffing position and the use of a Glidescope (GlideScope® Video laryngoscope; GVL®) with minimal mouth opening is one approach of securing the airway. The use of a laryngeal mask airway (LMA) should be seriously questioned. Establishing endotracheal intubation under emergency conditions is extremely challenging resulting in significant morbidity and mortality (Reviewed in Kilmartin et al., 2014).

In cases where adequate mouth opening is questionable, an awake fiberoptic nasotracheal intubation is recommended.

Patients who cannot open the mouth. In patients who present with fusion of the cervical vertebrae, limited mouth opening, or ankylosis of the TMJ, oral access for endotracheal intubation is not possible. For these patients, an awake fiberoptic nasotracheal intubation under light sedation is recommended. Dexmedetomidine may be a reasonable choice. This should be performed by well-trained anesthesia teams who are experienced with this type of procedure (Tumolo et al., 2006; Kilmartin et al., 2014). The team should consist of two experienced anesthesiologists. A back-up surgeon (usually an otorhinolaryngologist) experienced in performing tracheostomies should be present with an immediately available tracheotomy tray. Nasal fiberoptic endotracheal intubation is performed with attention to administration of vasoconstrictors to the nose and the use of lubricated nasopharyngeal tubes starting with a small one and increasing the diameter up to 32-34 Fr. All patients who undergo intubation should receive prophylactic steroids (methylprednisolone 50 mg iv q6 hrs, followed by oral prednisone taper once tolerating oral intake) to decrease the risk of fatal airway swelling and edema.

Perioperative pain management and regional anesthesia:

Most patients with FOP present with advanced ossifications at the thoraco-lumbar area precluding access to spinal or epidural analgesia. Furthermore, such an approach can lead to catastrophic flare-ups.

Patients who are receiving preoperative pain medications including opioids may present significant intraoperative management challenge to the anesthesiologist. The use of intravenous ketamine should be considered. The use of opioids should be minimized to avoid postoperative respiratory depression. The use of acetaminophen and nonsteroidal anti-inflammatory medication is advised after discussion with the surgeon. Postoperative pain management should be accomplished with intravenous medications. Patients using patient controlled analgesia (PCA) devices should receive supplemental oxygen with careful monitoring of oxygenation at all times. Oral medications should be prescribed to patients who can open the mouth.

All questions regarding general anesthesia should be directed to Dr. Zvi Grunwald (please see above).

References

Kilmartin E, Grunwald Z, Kaplan FS, Nussbaum BL. General anesthesia for dental procedures in patients with fibrodysplasia ossificans progressiva: a review of 42 cases in 30 patients. **Anesth Analg** 118: 298-301, 2014

Tumolo M, Moscatelli A, Silvestri G. Anaesthesia management of child with fibrodysplasia ossificans progressiva. **Br J Anaesth** 97: 701-703, 2006

22. Acceptable/Low Risk Procedures in FOP

In FOP, it is important to avoid soft-tissue trauma as it is likely to induce flare-ups and rapidly progressive HO, with resultant permanent loss of motion in the affected area (Kitterman et al., 2005). All invasive procedures in an FOP patient carry risk. Although patients with FOP must occasionally undergo medical procedures, the range of acceptable/low risk procedures remains undefined, so performing any procedure must be judged considering the potential risks and the benefits.

Injection and Venipuncture

Intramuscular injections and immunizations should be avoided, because they can lead to permanent loss of movement (Kitterman et al., 2005). Intracutaneous or subcutaneous injections are considered acceptable. No immunizations should be given while the patient is experiencing an active flare-up.

Local anesthesia can be risky, but may be acceptable for dermatologic procedures such as mole removal, if needed. For other indications, please consult directly with an FOP expert. For dental use, please see section on dental anesthesia.

Blood sampling can be safely performed from subcutaneous veins. Peripheral intravenous catheterization is also considered safe, if atraumatic. Placing femoral vein and radial artery catheters without any complications is reported (Liu et al., 2014), but is considered very high risk. Arterial catheterization will cause HO and is routinely forbidden.

Tracheal Intubation and Tracheostomy

Tracheostomy should be done as a last resort but must be carefully planned due to the possibility of HO of the anterior neck. Provisions should be made in the event a tracheostomy is needed.

Surgery and Other Invasive Procedures

In many children with FOP, tender soft-tissue masses initially develop mainly on the head, neck, or back (Kitterman et al., 2005). Without the previous diagnosis of FOP, clinicians tend to suspect neoplasm, leading to high rates of biopsy and/or resection surgery, with subsequent HO (Kitterman et al., 2005, Zaghoul et al., 2014). Orthopedic surgeries to remove HO or to correct deformities in the extremities or trunk have been reported, but most of them lead to HO and worsening of motion/deformity, even though medications to prevent inflammation and ossification were used perioperatively.

Reports on other invasive procedures are limited and the safety is not established. Lumbar puncture as a routine work-up for an intractable fever in an infant led to flare-up (Zaghoul et al., 2014). Emergent laparotomy for peritonitis evoked no HO (Okamoto et al., 2020). Physiotherapy is reported to induce permanent complications (Kitterman et al., 2005). However, the range of acceptable physiotherapy procedures has not been established. Passive range of motion exercises to gain additional range of joint motion should be avoided, but gentle active exercise may be permitted.

References

Kitterman JA, Kantanie S, Rocke DM, Kaplan FS: Iatrogenic harm caused by diagnostic errors in fibrodysplasia ossificans progressiva. **Pediatrics** 116: e654-e661, 2005

Liu JX, Hu R, Sun Y, Jiang H: General anesthesia in fibrodysplasia ossificans progressiva: a case report and clinical review. **Int J Clin Exp Med** 7:1474-1479, 2014

Okamoto N, Tazaki T, Shintakuya R, Hirano T, Sasaki M, Takahashi S, Nakamitsu A: Fibrodysplasia ossificans progressiva with two emergency laparotomies: A case report. **Int J Surg Case Rep** 73: 196-198, 2020

Zaghloul KA, Heuer GG, Guttenberg MD, Shore EM, Kaplan FS, Storm PB: Lumbar puncture and surgical intervention in a child with undiagnosed fibrodysplasia ossificans progressiva. **J Neurosurg Pediatr** 1: 91-94, 2008

23. Neurological Issues in FOP

Neurological symptoms are commonly reported by FOP patients. To determine the prevalence of neurological symptoms and their characteristics in individuals with FOP, a worldwide survey was conducted of the 470 patient members of the International FOP Association (IFOPA) using a questionnaire about neurological symptoms. There were 168 responses (105 females, 63 males; age 1.5-68 years) from 30 countries representing 36% of IFOPA members.

Chronic neurological symptoms were reported by 86 (51%). Prevalence of neuropathic pain (NP) was significantly increased ($P < 0.001$) compared to the general population, and tenfold more common in females (15%) than males (1.6 %). Of those with NP, 94 % reported other sensory abnormalities. Prevalence of recurrent severe headaches (HA) (26 %) was similar to that in the general population, but prevalence in females with FOP (36%) was almost fourfold greater than in males. Prevalence of NP, HA, and other sensory abnormalities was substantially higher in post-pubertal females; 33 % reported symptoms worsened during menstrual periods. Worsening of neurological symptoms during FOP flare-ups was reported by 23%. Three patients with FOP (1.8%) reported myoclonus, prevalence much greater than reported in the general population ($P < 0.001$). This worldwide survey indicated that neurological symptoms are common in FOP. These symptoms are plausibly related to dysregulated BMP signaling in the central and/or peripheral nervous systems (Kitterman et al., 2012).

To further elucidate these atypical neurologic symptoms, two mouse models of dysregulated BMP signaling relevant to FOP were evaluated for potential CNS pathology through non-invasive magnetic resonance imaging (MRI) studies and histological and immunohistochemical approaches. In one model, BMP4 was over-expressed under the control of the neuron-specific enolase promoter; the second model is a knock-in of the classic FOP mutation in ACVR1. MRI scans of four FOP patients were retrospectively examined. Demyelinated lesions and focal inflammatory changes of the CNS in both mouse models were consistently observed but not in wild-type controls. CNS white matter lesions were also found in each of the four FOP patients examined.

These findings suggest that dysregulated BMP signaling disturbs normal homeostasis of target tissues, including CNS where focal demyelination may manifest as the neurologic symptoms frequently observed in FOP (Kan et al., 2012). While most CNS lesions in FOP patients are incidental, asymptomatic and well-compensated, consistent developmental findings in the CNS in some of the severe FOP variants support the

hypothesis that over-activity of BMP signaling may have consequences for development and repair of the CNS (Kaplan et al., 2015; Severino et al., 2016).

Practically and in summary, patients with FOP have reported a higher incidence of neurological concerns including pain both during and outside of an FOP flare-up. The sources of pain should be carefully explored. Some individuals with FOP report chronic headaches as noted above. If headaches persist, patients should be referred to a neurologist, who can make recommendations for treatment.

References

Severino M, Bertamino M, Tortora D, Morana G, Uccella S, Bocciardi R, Ravazzolo R, Rossi A, Di Rocco M. Novel asymptomatic CNS findings in patients with ACVR1/ALK2 mutations causing fibrodysplasia ossificans progressiva. **J Med Genet** 53: 859-864, 2016

Kan L, Kitterman JA, Procissi D, Chakkalakal S, Peng C-Y, McGuire TL, Goldsby RE, Pignolo RJ, Shore EM, Kaplan FS, Kessler JA. CNS demyelination in fibrodysplasia ossificans progressiva. **J Neurol** 259: 2644-2655, 2012

Kaplan FS, Kobori JA, Orellana C, Calvo I, Rosello M, Martinez F, Lopez B, Xu M, Pignolo RJ, Shore EM, Groppe JC. Multi-system involvement in a severe variant of fibrodysplasia ossificans progressiva (ACVR1c.772G>A; R258G): a report of two patients. **Am J Med Genetic A**167A:2265-2271, 2015

Kitterman JA, Strober JB, Kan L, Rocke DM, Cali A, Peeper J, Snow J, Delai PLR, Morhart R, Pignolo RJ, Shore EM, Kaplan FS. Neurological symptoms in individuals with fibrodysplasia ossificans progressiva. **J Neurol** 259: 2636-2643, 2012

24. Hearing Impairment in FOP

Hearing impairment is a common feature of FOP and occurs in approximately 50 percent of patients. The onset is usually in childhood and may be slowly progressive. Hearing loss is usually conductive in nature and may be due to middle ear ossification, but in some patients, the hearing impairment is neurologic in nature. Children with FOP should generally have audiology evaluations every other year; more often, if necessary. Hearing aids are often helpful and can diminish developmental problems due to hearing loss (Levy et al., 1999). Acute hearing loss is not usually associated with FOP and should prompt evaluation for other causes.

References

Levy CE, Lash AT, Janoff HB, Kaplan FS. Conductive hearing loss in individuals with fibrodysplasia ossificans progressive. **Am J Audiol** 8: 29-33, 1999

25. Gastrointestinal Issues in FOP

According to baseline data collected by the IFOPA Registry (Mantick et al, 2018) almost 28% of all patients report at least one health issue related to the stomach and digestion. Abdominal pain was the most common complaint, accounting for about 18% of all participants, followed by symptoms of gastrointestinal reflux and nausea. Abdominal pain was highest in females over the age of 17. Difficulty swallowing was reported in up to 19% of males age 18 years or older. Loss of appetite was most common among adult

females. Rectal complaints, including constipation, was present in about 10% of adult patients, more than twice as much compared to those under the age of 18. Severe diarrhea was a complaint in approximately 5% of patients. Trouble digesting food and complaints of intermittent vomiting represented about 7.5% and 9% of all registry participants, respectively. Overall, the subgroup most affected by gastrointestinal issues is adult females, and the subgroup least affected is females under the age of 18. It is unclear at the present time if the prevalence of these complaints is greater than those in the general population, demographically matched, or if the etiologies of these complaints differ based on the diagnosis of FOP.

References

Mantick N, Bachman E, Baujat G, Brown M, Collins O, De Cunto C, Delai P, Eekhoff M, Zum Felde R, Grogan DR, Haga N, Hsiao E, Kantanie S, Kaplan F, Keen R, Milosevic J, Morhart R, Pignolo R, Qian X, di Rocco M, Scott C, Sherman A, Wallace M, Williams N, Zhang K, Bogard B. The FOP connection registry: Design of an international patient-sponsored registry for Fibrodysplasia Ossificans Progressiva. *Bone* 109:285-290, 2018

26. Kidney Stones & FOP

Clinical observations prompted a worldwide survey of patient-members of the International Fibrodysplasia Ossificans Progressiva Association (IFOPA) on the disease burden of kidney stones. The survey examined risk factors for the development of kidney stones in FOP patients, and provided a basis for prevention of stones in this already devastating disease (Gupta et al., 2018).

Although geographical variation exists, patients with FOP have approximately a two-fold higher prevalence of kidney stones than the general population. Immobilization coupled with increased bone turnover is a significant risk factor in the development of kidney stones in this population. There has been no comprehensive study of stone composition in FOP patients.

A low-fiber diet was the only dietary factor in this study to significantly increase the risk of developing kidney stones in this population, although deficient water intake and excess animal protein intake were associated with the condition. FOP patients with a history of urinary tract infections are at increased risk for developing kidney stones. Extracorporeal shock wave lithotripsy, uteroscopic stone removal, percutaneous nephrolithotomy, and laser lithotripsy have all been used as treatment modalities, but there are no long-term data to evaluate the safety or efficacy of one treatment over another.

Ideally, recommendations to prevent kidney stones are made. This becomes increasingly important as FOP patients become progressively more immobilized. Patients should (Gupta et al., 2018):

- Drink sufficient water to keep the urine volume above three liters daily.
- Substitute whole wheat bread for white bread and eat natural fiber cereals.
- Limit their intake of Vitamin C and oxalate-rich foods.
- Refrain from adding salt to their food.
- Not restrict dairy products; however, they should be careful not to overindulge either.

References

Gupta RR, Delai PLR, Glaser DL, Rocke DM, Al Mukaddam M, Pignolo RJ, Kaplan FS. Prevalence and risk factors for kidney stones in fibrodysplasia ossificans progressiva. **Bone** 109: 120-123, 2018

27. Rehabilitation Issues in FOP

As degenerative joint disease advances and heterotopic bone accumulates in FOP, range of motion is progressively lost, leading to near complete immobility (Pignolo et al., 2016; Kaplan et al., 2017; Kaplan et al., 2018; Pignolo et al., 2018). Until this process can be halted or reversed, the focus of rehabilitation approaches should be on preserving and promoting independence and enabling activity and participation in daily living. Occupational therapy and vocational education consultations may be extremely useful. Although protected active range of motion such as warm water hydrotherapy is encouraged, passive range of motion must be avoided, as it risks exacerbation of FOP with further loss of function and pain. Despite widespread HO and progressive disability, most individuals with FOP lead productive and fulfilling lives (Levy et al., 1999; Levy et al., 2005).

Many of the limitations exacerbated by disease progression can be ameliorated with thoughtful rehabilitation.

Occupational Therapy Interventions: Dressing may be enabled with pullover shirts and blouses, elastic waistbands, Velcro closures, sock donners (devices where the sock is placed over a cuff attached to a cord), elastic shoelaces, and long handled shoehorns and reachers. Raised toilet seats, custom-angled commodes, bedside urinals (shaped for men or women), and bidets all enable toileting. Widened doorways, tub and bath benches (which may need to be customized to fit the individual) and grab bars increase bathroom safety and accessibility. Long-handled sponges, combs, or modified reachers, electric toothbrushes, water pics, and suction devices help insure cleanliness and personal hygiene.

Strategically placed stools and elevated platforms, long-handled eating utensils and straws, help at the dinner table. Meal preparation may be facilitated by electrical can and jar openers, cutting boards with spikes to hold food while it is prepared or cut, and rotating shelves (Lazy Susans). For individuals with limited ability to masticate, food may be ground-up or pureed.

Depending on the stage of disease progression, canes, walkers, crutches, and/or custom shoes may be essential aids to ambulation. The assistance of thoughtful orthotists to fabricate adaptive shoes and inserts should be considered. For more severe limitations, power wheelchairs may be necessary. Considerations for power wheelchairs include customized seating, power seat elevation and depression, anterior and posterior tilt and recline functions. Lap trays with mounts for laptop computers allow participation in work and school.

Vocational and Educational Issues: Because even minor trauma can trigger disabling HO, it is sensible to encourage intellectual pursuits and computer skills as alternatives to physical activity. The **Individuals with Disabilities Education Improvement Act of 2004 (IDEA 2004)** is a law in the United States that mandates equity, accountability and excellence in education for children with disabilities. This requires public school systems to provide each disabled child with an individualized educational plan, and an education in the least restrictive environment. Children are entitled to occupational, physical and speech therapy as well as classroom aides, if indicated. Each state is required to offer some sort of vocational rehabilitation to help people with disabilities enter or remain in the work force.

Transportation and Home Modification: Vans can be customized to accept an FOP power chair. Ramps and lifts can be installed, roofs can be raised, floors can be lowered, new controls and motors can be installed to allow the van to “kneel”, lowering ground clearance to ease ascent into a van. Home modifications include elimination or minimization of indoor steps, installation of grab bars as well as exterior and interior ramps, widened hallways, accessible bathrooms and kitchens. Environmental control units (which may be integrated as smart phone applications) operate appliances, doors, and televisions remotely. To facilitate sleep, there are tilt table beds that rotate from vertical to horizontal, specialized mattresses and overlays to redistribute pressure to provide comfort and protect skin integrity.

Sexuality and reproduction: Physical acts of sexual intimacy require tact and thoughtfulness. Pillows and bolsters may be necessary to support the unusual and inflexible postures. Genetic counseling and discussion of contraception are warranted for the sexually active or those who are considering such activity, especially if they or a partner are in a clinical trial and/or on an investigational agent.

Recreational therapy may be helpful in making meaningful use of leisure time. Psychologists, social workers and other mental health counselors can help affected individuals and family members with adjustment to the limitations and inconveniences imposed by FOP. Creative arts therapies (art therapy, music therapy, dance/movement therapy, drama therapy, poetry therapy) use arts-based methods and creative processes for the purpose of ameliorating disability and illness and optimizing health and wellness.

Many of these rehabilitation treatment approaches can be delivered, at least in part, directly to the home via telehealth.

Aquatic therapy (warm water hydrotherapy) allows individuals to perform active range of motion, cardiopulmonary, and resistive exercise in a safe, low impact environment. Warm water can facilitate pain relief. Modified lifts, elevators or ramps may be necessary for pool entry and exit.

Iontophoresis involves the introduction of topically applied physiologically active ions (acetic acid, steroids) through the epidermis using continuous direct current. Anecdotal reports suggest that acetic acid iontophoresis may help restore some lost temporomandibular joint range of motion in FOP.

For questions on rehabilitation for FOP patients, please contact:

Charles Levy, MD

Chief, Physical Medicine and Rehabilitation Service
North Florida/South Georgia Veterans Health Service
Adjunct Associate Professor, Department of Occupational Therapy
Research Scholar, Center for Arts in Medicine
University of Florida
1601 S.W. Archer Road
Gainesville, Florida 32608, USA
Tel: 800 324 8387 Ext 6922: Fax: 352-374-6167
Email: levyce@aol.com

References

Kaplan FS, Al Mukaddam M, Pignolo RJ. A cumulative analogue joint involvement scale for fibrodysplasia ossificans progressiva (FOP). **Bone** 109: 123-128, 2018

Kaplan FS, Al Mukaddam M, Pignolo RJ. Longitudinal patient-reported mobility assessment in fibrodysplasia ossificans progressiva (FOP). **Bone** 109:150-161, 2018

Levy CE, Berner TF, Bendixen R. Rehabilitation for individuals with fibrodysplasia ossificans progressiva. **Clin Rev Bone Miner Metab** 3: 251-256, 2005

Levy CE, Berner TF, Sandhu PS, McCarty B, Denniston MA. Mobility challenges and solutions for fibrodysplasia ossificans progressiva. **Arch Phys Med Rehab** 80: 1349-1353, 1999

Pignolo RJ, Bedford-Gay C, Liljestrom M, Durbin-Johnson BP, Shore EM, Rocke DM, Kaplan FS. The natural history of flare-ups in fibrodysplasia ossificans progressiva: a comprehensive global assessment. **J Bone Miner Res** 31:650-656, 2016

Pignolo RJ, Durbin-Johnson BP, Rocke DM, Kaplan FS. Joint -specific risk of impaired function in fibrodysplasia ossificans progressiva (FOP). **Bone** 109:124-133, 2018

28. Aids, Assistive Devices, and Adaptations (AADAs)

Effects on global health by use of AADAs

Aids, assistive devices and adaptations (AADAs) are frequently used by individuals with FOP. In a study on 299 FOP patients from 54 countries, based on data from the International FOP Association (IFOPA) Global Registry, there was an increase in the use of AADAs by age groups, but no difference on the basis of gender for all participants (Pignolo et al., 2020). The median number of AADAs was 2.0 for the 0–<9 years age group, 7.5 for the 9–15 years age group, and 13.0 for the >15 years age group. The most commonly used AADAs, each by >40% of all participants, were bathing attendants, straws for drinking, reaching sticks, and memory foam bed mattresses.

The use of some AADAs were associated with improvement in global health scores, including customized motorized wheelchairs, drinking draws, portable urinals, pill crushers, roll-in showers, portable commodes, airflow mattresses, ramps for home entry, automatic lights, customized counters, durable flooring, remote control entry, adaptive keyboards, adaptive chairs, special electronics, adapted vehicles for motorized wheelchairs, wide doorways for wheelchair access, voice activated computer software, typing sticks, and onscreen keyboards not normally part of devices.

Anticipatory guidance for AADAs

It is difficult to predict when a given individual with FOP will first experience impairment in activities of daily living that can be mitigated by AADAs. However, based on use by at least 10% of IFOPA Global Registry participants, it is possible to give anticipatory guidance on the type of ADAAs that are likely to be required over the natural course of the disease (Table). Evaluation of AADA use among age groups provides several high-level recommendations: (1) There are several AADAs that are valuable across all age groups, including bathing attendants, part-time home personal care attendants, straws for drinking, reaching sticks, customized clothing, memory foam bed mattresses and pillows, floor level thresholds on all doorways, and customized furniture; (2) Among personal care tools and aids, dressing sticks and hearing aids become very helpful or required, respectively, beginning at 9 years of age; (3) Many bathroom aids and devices are frequently employed by age 9; (4) Home adaptations are generally required after the age of 15; (5) Occupational therapy and devices used to preserve pulmonary function are useful over the entire life span.

Aids, Assistive devices, and Adaptations (AADAs)*			
	Age group (years)		
AADAs	0 - < 9	9-15	> 15
Mobility Aids			
Cane/crutch			
Manual wheelchair			
Motorized scooter			
Customized motorized wheelchair			
Adapted vehicle for motorized wheelchair (ramp, lift, or roof adaptations)			
FOP-Specific Care Attendants (paid or unpaid)			
Bathing attendant(s)			
Part-time home personal care attendant(s)			
Full-time personal school aide (paid or unpaid)			
Eating Tools			
Adapted eating utensils			
Customized height table for eating			
Customized chair for eating			
Straws for drinking			
Blender for pureeing foods			
Personal Care Tools/Aids			
Hearing aids			
Reaching stick			
Dressing stick			
Customized clothing			
Standard shoe lift for support			
Customized shoe soles			
Portable urinal for male and female			
Adapted comb, brush, bathing tools, tooth brush, shaver, or cosmetic application tools			
Pill crusher			
Medical alert bracelet with annual emergency membership			
Customized dental care tools			
Bathroom Aids and Devices			
Barrier-free roll-in shower			
Shower seat/chair			
Handicap height toilet			
Washlet toilet (push button washing)			
Lift seat on toilet			
Adapted sink counter, height, faucet handles, or piping			
Shower grab bars			
Shower hand held sprayer			
Bathroom grab bars			
Bedroom Aids and Devices			
Memory foam bed mattress			
Memory foam pillows			
Bed with motorized lift system			
Airflow mattress			
Bed safety rails			

Remote control devices for lights, window treatments, and/or shades				
Home Adaptations				
Floor level threshold on all doorways				
Wide doorways to allow wheelchair access				
Permanent built in ramp for home				
Portable ramp for use in home, office, or travel				
Customized furniture				
Customized counters in your kitchen, bathroom, or work area				
Lift chair				
Durable/easy care flooring due to wheelchair weight				
Padded flooring for protection for children				
Combination emergency fire/CO detectors and 911 alert				
Work Environment Adaptations				
Customized desk				
Customized workstation				
Use of handicapped bathroom facilities				
Technology Adaptations				
Adapted keyboard (small, rocker, or customized)				
Wireless keyboard and mouse				
Adapted stand for computer use				
Onscreen keyboard that is not normally part of the device				
Sports and Recreation Adaptations				
Protective helmet				
Adapted bicycle				
Other adapted recreational gear				
School Adaptations				
Adapted desk				
Adapted chair				
Special electronics for learning				
Adapted curriculum				
Medical Therapies for Daily Living				
Physical therapy				
Hydro therapy				
Occupational therapy				
Pep mask or spirometer for breathing exercises				
*Based on data from the IFOPA Global Registry and responses from 299 individuals. Shading indicates use of AADA by at least 10% of respondents.				

Practical experience suggests that patients and families seek AADAs when a physical limitation demands remediation and support rather than in anticipation of such limitation. This reactionary behavior causes excessive stress in a time when the patient is already experiencing extreme challenges of overcoming new limitations from the progression of the disease. This is often the result of social support systems that, although well intentioned, enable dependent behaviors rather than empower independent activities through the early utilization of AADAs. An approach to reduce enabling behaviors and encourage patient independence through AADA use is to introduce the tool or adaptation prior to its need, in a setting where it is visible and promoted by the entire family. For example, providing a child (who has not yet lost mobility) with a reaching device and taking turns with them picking out socks from the laundry basket. In this way

there is a greater chance for acceptance and use of the tool or adaptation because time is given for the emotional and physical adjustment period before the need is actually realized. The window of opportunity for introduction of an AADA must be considered in light of the usual sequence of events—from pre-limitation, to limitation, initial AADA resistance, and slow acceptance. This anticipatory planning has the potential to provide patients with increased opportunities for success using AADAs leading to improved coping skills, greater resiliency, increased emotional intelligence and overall social-emotional well-being as the disease progresses.

Most commonly recommended AADAs

The following have been identified as some of the most commonly used AADAs based on consultations and inquiries made by medical support staff and FOP community members, respectively, to the IFOPA. For AADA consultations and personalized support go to www.ifopa.org/ability_toolbox_program.

Most common Early Childhood AADAs:

- Protective headgear (helmets, impact-reducing headbands) to protect the head and face during falls
- Gait trainers to assist with balance when learning to walk
- Adaptive strollers that provide extra cushion and support for community transportation
- Floor padding and bumpers for safe floor play
- Sink faucet extenders to shorten the reaching distance when washing hands
- “Nosey” cups – cups with a section of rim removed to make space for the nose so that head extension is not necessary for drinking
- Bendable foam tubing grips to improve grasp and holding angle of flatware, toothbrushes, and/or pencils

Most common School-Aged and Young Adult AADAs:

- Dressing sticks and long-reach shoehorns to assist with dressing
- Adaptive clothing with additional zippers, Velcro, or magnetic closures
- Adaptive desk chairs that swivel to allow full visual field despite reduced neck mobility
- Adaptive desk with adjustable height to accommodate adaptive seating or wheelchairs
- Table-top slant boards to support easier viewing and writing angles on assignments/documents
- Keyboard typing aids
- “Pick Me” stick or visual aid to extend in lieu of child raising hand to be called upon in class
- Bean bag chairs for more comfortable seating when on the floor
- Individualized Educational Plans to allow for necessary accommodations in school (flexible seating, longer test durations, early release when transitioning between classes to avoid crowded hallways and risk of falls, alternate activities during Physical Education classes, para-professional assistance)
- Adaptive bicycles and recreational gear
- Toilet wiping aids
- Hair washing tools
- Emergency ID bracelets to inform First Responders, school staff, and/or employers of FOP dx and contraindications

Most common Adult AADAs:

- Extended eating utensils and adaptive dishware (high-sided plates for easier scooping, plates with spikes to hold food in place while cutting)
- Bathing and hygiene tools, adaptive combs/brushes, adaptive shavers, adapted cosmetic make-up applicators

- Adapted toilets (Bidet toilet seats, toilet risers, grab bars or side rails for support, portable commodes and urinals)
- Shower chairs and zero-entry (“roll-in”) showers
- Canes, Lofstrand crutches or rolling walkers to assist with balance when walking
- Motorized scooters to assist with mobility for extended distances
- Custom motorized wheelchairs for non-ambulators and wheelchair accessories (i.e. trays, mounts for cell phones and tablets, cup holders, custom-placed joystick controls based on upper extremity positioning)
- Cushions and seating solutions to prevent pressure sores
- Wheelchair access ramps, both permanent and portable, allowing access into home environments and public spaces
- Accessible vans for transporting wheelchair users

Individuals with FOP tend to use AADAs available in the marketplace as well as homemade tools they have personally crafted for their individual needs. Knowledge and accessibility of AADAs vary greatly across the globe; therefore, encouraging patients to use creativity and a problem-solving mindset to generate solutions to their mobility challenges is vital to their success with independence. Everyday items such as coat hangers, duct tape, dowel rods or sticks, and pipe or tubing can be used to construct a tool that helps a patient reach, scratch, push and pull in order to complete a task, demonstrating that expensive AADAs found in the marketplace can be simulated and are often not necessary. While referring patients to the IFOPA for support with AADAs is encouraged, it is also recommended to seek input from the national FOP organizations for country-specific resources as availability of AADAs, cost, healthcare assistance, and importing restrictions vary greatly by geographic location.

Description of online resources for AADAs

In addition to finding AADAs through internet searches, adaptive equipment catalogs and recommendations from allied health professionals, there is a collection of online resources for AADAs available on the IFOPA website at guidebook.ifopa.org. The AADAs in the Online Guidebook can be downloaded and printed for those without web access, and the entire resource has a translation feature using Google Translate. This resource is an ever-changing library of AADAs reflecting the current trends of tool use in the FOP community throughout the world and is updated as new tools are discovered and submitted to the IFOPA.

For individualized support beyond AADAs listed in the Online Guidebook, medical professionals are encouraged to refer patients to:

- Family support programs (www.ifopa.org/support_groups)
- IFOPA Family Services Coordinator and Ability Toolbox program (www.ifopa.org/ability_toolbox_program)
- Harold & Elaine Kaplan Quality of LIFE Award program for financial support for AADAs (www.ifopa.org/quality_of_life_award)

Medical professionals may also request a sample demonstration kit of commonly used AADAs for their office to share with families during office visits.

- Doctor’s Medical Tool Kit of sample AADAs (www.ifopa.org/ability_toolbox_program)

References

Pignolo RJ, Cheung K, Kile S, Fitzpatrick MA, DeCunto C, Al Mukaddam M, Hsiao EC, Baujat G, Delai P, Eekhoff EMW, Di Rocco M, Grunwald Z, Haga N, Keen R, Levi B, Morhart R, Scott C, Sherman A, Zhang K, Kaplan FS. Self-reported baseline phenotypes from the International Fibrodysplasia Ossificans Progressiva (FOP) Association Global Registry. *Bone*. 2020;134:115274. Epub 2020/02/18. doi: 10.1016/j.bone.2020.115274 PubMed PMID: 32062004

29. Pregnancy Issues in FOP

The decision to have a child is one of the most important and serious life decisions an individual or couple can make. Because FOP is an inherited disease, anyone (man or woman) with FOP will have similar concerns about passing the FOP mutation to his/her child. If a parent has FOP, the chance that the child will have FOP is fifty percent. Women, specifically, have additional matters to consider. In addition to the usual risks that any woman might encounter during pregnancy, a woman with FOP has additional concerns that must be carefully considered (Davidson et al., 1985; Fox et al., 1987; Thornton et al., 1987; Muglu et al., 2012).

Pregnancy is a rare event in FOP; however, it is possible for a woman with FOP to carry a child (Muglu et al., 2012). However, pregnancy and childbirth have substantial life-threatening risks to both the mother and child and present unique management challenges. If pregnancy is contemplated by a woman with FOP, pre-pregnancy counseling is mandatory.

FOP results in breathing difficulties during the latter part of pregnancy because of restrictive chest wall disease due to developmental anomalies in the costovertebral joints and progressive HO in the chest muscles and abdominal wall. Careful monitoring including respiratory function tests may be required during the antepartum and intrapartum course to establish any requirement for respiratory support.

A pregnancy, even with an unaffected fetus, poses substantial risks to a mother with FOP. Although data are scant, one of the initial risks of pregnancy associated with FOP is a risk of miscarriage or substantial risk of premature birth following spontaneous preterm labor and may be secondary to fetal distress encountered during the later stages of pregnancy. Steroid administration for fetal lung maturity is imperative if delivery is anticipated before 36 weeks of gestation (Muglu et al., 2012).

Another substantial risk is thromboembolism, which is exacerbated by severe immobility of FOP in addition to the hyper-coagulable state of pregnancy. The added constraint of lower limb edema that invariably occurs in the last trimester of pregnancy further increases the risk of this life-threatening complication and warrants consideration of the use of prophylactic low-molecular-weight heparin throughout the duration of pregnancy (Muglu et al., 2012).

In addition to substantial risk to a mother with FOP, pregnancy also poses substantially increased risks to the unborn child including the risk of FOP (50%), prematurity, fetal distress and the risk of complications from requisite general anesthesia. One of the specific risks to the mother associated with FOP is a flare-up during pregnancy. The chronic use of high-dose glucocorticoids and non-steroidal anti-inflammatory medications has potential embryonic and fetal toxicity and their use should be avoided, when possible.

The management of miscarriage, delivery and antenatal care poses substantial difficulties because of the specific risks associated with FOP. Vaginal delivery is perilous in a woman with FOP due to severe pelvic deformity as well as fusion of the lumbar spine, hip joints and sacroiliac joints. Delivery by caesarean section is the only relatively safe mode of delivery after the age of viability is achieved (Muglu et al., 2012).

In addition to the physical problems associated with delivery, the choice of anesthesia becomes a challenge due to technical difficulties with both regional and general anesthesia. Regional anesthesia is technically difficult due to pre-existing heterotopic bone and the danger of precipitating new episodes of HO following an epidural block. Similar problems, including ossification in tracheal rings and the danger of overstretching the jaw, may cause difficult intubation during general anesthesia. Also, it is impossible to extend the neck in young adults with FOP due to orthotopic ankylosis of the cervical paravertebral joints that ossify in childhood, even before the appearance of HO. The use of awake fiberoptic nasotracheal intubation was found to be the only safe option. At delivery, there should be a team skilled in resuscitation of high-risk infants (Muglu et al., 2012; Kilmartin et al., 2014).

Many reports describe exacerbation of FOP following surgical procedures. However, in other cases (five surgical operations including two hysterectomies), no HO formed in the abdominal wall. The use of prednisone or intravenous equivalent at the time of elective surgery and three days following surgery is recommended if there are no other contraindications. The rational use of corticosteroids early in the course of an FOP flare-up is based primarily on its potent anti-inflammatory effects and on emerging knowledge of the importance of inflammatory triggers in FOP flare-ups (Muglu et al., 2012).

Although *in vitro* fertilization, pre-implantation genetic testing, embryo selection and surrogate motherhood are theoretically possible now after the gene discovery, that sequence has not been reported for FOP. Prenatal genetic diagnosis could potentially be used to exclude FOP (Du et al., 2010).

In summary, although pregnancy in women with FOP is possible, FOP poses major life-threatening risks to mother and child as well as life altering consequences to the entire family if a child is born with this condition. Pregnancy in FOP should never be undertaken without serious consideration and family planning. Unwanted pregnancies should be assiduously avoided. Independent genetic counseling is available, if desired. Should a pregnancy occur, guidance and care at a high-risk pregnancy center are imperative.

References

- Davidson BN, Bowerman RA, La Ferla JJ. Myositis ossificans progressiva and pregnancy. A therapeutic dilemma. **J Reprod Med** 30: 945-947, 1985
- Du J, Huang LL, Tan YQ, Cheng DH, Li SF, Li LY, Lu GX. Mutation analysis and prenatal Exclusion of Fibrodysplasia Ossificans Progressiva in a Chinese fetus. **Genet Test Mol Biomarkers** 2010 Jan 10
- Fox S, Khoury A, Mootabar H, Greenwald EF. Myositis ossificans progressiva and pregnancy. **Obstet Gynecol** 69 (Pt 2):453-455, 1987
- Kilmartin E, Grunwald Z, Kaplan FS, Nussbaum BL. General anesthesia for dental procedures in patients with fibrodysplasia ossificans progressiva: a review of 42 cases in 30 patients. **Anesth Analg** 118: 298-301, 2014
- Muglu JA, Garg A, Pandiarajan T, Shore EM, Kaplan FS, Uchil D, Dickson MJ. Pregnancy in fibrodysplasia ossificans progressiva. **Obstet Med** 5:35-38, 2012

Thornton YS, Birnbaum SJ, Lebowitz, N. A viable pregnancy in a patient with myositis ossificans progressiva. **Am J Obstet Gynecol** 156: 577-578, 1987

30. FOP Variants

[Adapted from “FOP Variants: What Are They, Who Has Them & What Do They Mean for You? By Frederick S. Kaplan, M.D. and Eileen M. Shore, Ph.D.”]

When we started seeing FOP patients, nearly 35 years ago, it quickly became obvious that everyone shared two features: malformed big toes and progressive HO. These were clearly two characteristic clinical features and they defined classic FOP.

As we saw more patients, we recognized variability in the toe malformation that individuals had, as well as differences in the rate of progression of HO. For example, some had short, bent big toes; others had short, straight big toes; others still had long big toes and some were of normal length. But everyone had a toe malformation – most commonly characterized by a missing or malformed joint in the big toe that was obvious on physical examination, radiographs or both. Likewise, we noted variability in the rate of progression of the FOP HO – some progressed very rapidly while others progressed very slowly, and still others progressed at a more even pace. Much like other traits in any population, FOP showed a natural variation that defined the limits of the norm.

Occasionally though, we saw someone who had a feature of FOP that was WAY outside of the “normal” range – even for FOPers. This defining feature most often involved the big toes. Among these individuals, we began to recognize two groups: One group had nearly normal or completely normal-looking big toes. The other group had extremely severe toe malformations that involved other digits in the feet and the hands. In the more “severe” group, we observed additional developmental abnormalities in other organ systems. We refer to these two groups of outliers as “FOP variants” – some mild, some severe.

Approximately 97% of individuals that we have seen with FOP HO had “classic FOP”, and approximately 3% of individuals were “FOP variants.” About half the patients with FOP variants (1.5%) had a mild clinical variant and about half the patients (1.5%) had a severe variant. Again, these observations were based on clinical evaluation and preceded the discovery of the FOP gene.

After we discovered the FOP gene, we examined the DNA sequence of the FOP gene in all patients who we had seen. Remarkably, nearly every single patient who was diagnosed as having “classic FOP” – regardless of where they were on the spectrum of disease severity – had the same exact heterozygous missense activating FOP mutation: [ACVR1c.617G>A; p.R206H].

As remarkably, every single patient who we had identified clinically as an “FOP variant” had a different heterozygous missense activating mutation in the ACVR1 gene.

In other words, those with “classic FOP” as the clinical diagnosis had the same “classic mutation” in the FOP gene [ACVR1c.617G>A; p.R206H], while everyone clinically diagnosed as an “FOP variant” had a “variant mutation” in the FOP gene.

While many will ask, “Is the HO less severe in the less severe variants and more severe in the more severe variants?” The answer is: “Sometimes, but not necessarily.” **Some** of the patients with mild toe variants have a later onset and a milder course of HO and **some** of the patients with severe toe variants have an

earlier onset and more severe course of HO. But there is wide variability – just as there is in the onset and severity of HO in the patients with “classic FOP,” even among identical twins with classic FOP. The most important defining clinical feature of the “FOP variants” is the malformation of the big toes – either far less severe or far more severe than the patients with “classic FOP”.

Although the clinical assessment is extremely important in assigning a clinical status of “classic FOP” vs. “FOP variant”, the only way to ascertain the exact type of FOP at a molecular level is by genetic testing and DNA sequence analysis of the FOP gene. To be clear, the absolute defining factor in whether someone has “classic FOP” or an “FOP variant” is the exact genetic sequence of the ACVR1 (FOP) gene. If someone has the commonly shared ACVR1c.617G>A; p.R206H mutation, then they have “classic FOP”. If they have a variant genetic mutation in the ACVR1 gene, then they have an “FOP variant”. So far, there are approximately 20 identified variants in the FOP gene.

The evaluation of the FOP gene (ACVR1) by DNA sequencing can be conducted in a genetics laboratory through DNA obtained from a blood sample. The analysis can be arranged by your physician.

Genotyping is required for enrollment into all clinical studies and is important for proper clinical and genetic counseling.

Keep in mind that FOP variants are much rarer than classic FOP. Some of the ACVR1 variants have so far been found in only one or two affected individuals in the world, so it is difficult to make predictions about the course of FOP over time. With other variants, there may be a few affected individuals in the world, so we know a little bit more about the course that FOP variant may take over time.

So, what does this all mean for someone who has an FOP variant?

First, we have less knowledge and therefore less certainty about the FOP variants than we do about classic FOP; but, we and other scientists are beginning to learn more about how the ACVR1 variant mutations affect cell functions and how they are similar to and different from the classic ACVR1 mutation (Haupt et al., 2018; Mucha et al., 2018; Allen et al., 2020). The exact location and characteristic of the mutation in the ACVR1 gene (blueprint for the ACVR1 protein; classic vs. variant) informs the structural biologists with whom we work and collaborate to better understand the damaged workings of ACVR1 in FOP. That insight is critical to developing structural models and approaches to inactivating the damaged and overactive switch that leads to disabling HO in all forms of FOP.

Second, regardless whether someone has “classic FOP” or an “FOP variant”, all have over-activity of the bone forming BMP signaling pathway and thus the tendency to form heterotopic bone.

Third, whether someone has “classic FOP” or an “FOP variant”, the process by which they form heterotopic bone after birth is the same.

Fourth, the general precautions for FOP are the same for patients with classic FOP and FOP variants.

Fifth, the symptomatic management of flare-ups is the same for patients with classic FOP and FOP variants.

Sixth, some of the approaches to develop medications for FOP are mutation-specific while others target the broad process of HO common to both.

Seventh, approaches to specifically block the overactive ACVR1 receptor (encoded by the FOP gene) should be applicable to FOP variants as well as classic FOP.

Eighth, new clinical trials will likely be limited at first to patients who have classic FOP – and then later, if applicable, to those with FOP variants – based primarily on regulatory requirements.

Ninth, every measure and pressure are being exerted to open-up applicable clinical trials to patients with FOP variants as quickly and humanly possible. This is being done right now.

Tenth, and finally, all patients with FOP – classic and variant FOP – are part of the small but powerful worldwide FOP community. There is a common thread that unites everyone with FOP. All with FOP must stay together, speak with one voice, and learn from each other. Knowledge will lead to better treatments and a cure for all of those with FOP regardless of whether one has “classic FOP” or an “FOP variant”.

References

Allen, RS, Tajer B, Shore EM, and Mullins MC. Fibrodysplasia ossificans progressiva mutant ACVR1 signals by multiple modalities in the developing zebrafish. **eLife**. 9:e53761, 2020. doi: <https://doi.org/10.7554/eLife.53761> PMID: 32897189

Haupt J, Xu M, Shore EM. Variable signaling activity by FOP ACVR1 mutations. **Bone** 109: 232-240, 2018

Huning I & Gillessen-Kaesbach. Fibrodysplasia Ossificans Progressiva: Clinical Course, Genetic Mutations and Genotype-Phenotype Correlations. **Molec Syndromology** 5: 201-211, 2014

Kaplan FS, Kobori JA, Orellana C, Calvo I, Rosello M, Martinez F, Lopez B, Xu M, Pignolo RJ, Shore EM, Groppe JC. Multi-system involvement in a severe variant of fibrodysplasia ossificans progressiva (ACVR1c.772G>A; R258G): a report of two patients. **Am J Med Genetic A** 167:2265-2271, 2015

Kaplan FS, Xu M, Seemann P, Connor M, Glaser DL, Carroll L, Delai, P, Fastnact-Urban E, Forman SJ, Gillessen-Kaesbach G, Hoover-Fong J, Köster B, Morhart R, Pauli RM, Reardon W, Zaidi SA, Zasloff M, Mundlos S, Groppe J, Shore EM. Classical and atypical FOP phenotypes are caused by mutations in the BMP type I receptor ACVR1. **Human Mutation** 30: 379-390, 2009

Mucha BE, Hashiguchi M, Zinski J, Shore EM, Mullins MC. Variant BMP receptor mutations causing fibrodysplasia ossificans progressiva (FOP) in humans show BMP ligand-independent receptor activation in zebrafish. **Bone** 109: 225-231, 2018

VI. CURRENT TREATMENT CONSIDERATIONS

At the present time, there are no established preventions or treatments for FOP. The disorder's rarity, variable severity, and fluctuating clinical course pose substantial uncertainties when evaluating experimental therapies.

In evaluating each potential treatment, we have focused on the known mechanism of action of the drug as it relates to the proposed pathogenesis of FOP. Consideration for use of each medication was made based on balancing the clinical uncertainty of each agent when used to treat FOP against the compassionate need to adequately and safely control the disabling symptoms of the disease, especially during flare-ups. Each pharmacologic agent was classified into one of three categories based on experimental or anecdotal experience with the drug as well as knowledge of each drug's safety profile.

Class I: Medications that have been widely used to control symptoms of acute flare-ups in FOP (swelling and pain), or chronic arthropathy - with generally minimal side effects.

Examples: Short-term use of high-dose corticosteroids, and use of non-steroidal anti-inflammatory drugs (NSAIDs) and COX-2 inhibitors.

Class II: Medications that have theoretical application to various aspects of FOP, are approved for the treatment of other disorders, and have limited and well-described effects. *Examples:* Leukotriene inhibitors, mast cell stabilizers, aminobisphosphonates (Pamidronate; Zoledronate) and specific tyrosine kinase inhibitors (Imatinib).

Class III: Investigational new drugs

Examples: Selective ACVR1/ALK2 signal transduction inhibitors, monoclonal antibodies targeting Activin A or ALK2 and retinoic acid receptor gamma agonists.

PHYSICIANS TREATING PATIENTS WHO HAVE FOP SHOULD KEEP IN MIND THAT NONE OF THESE MEDICATIONS (OR ANY OTHER MEDICATIONS TO DATE) HAVE BEEN PROVEN TO ALTER THE NATURAL HISTORY OF FOP

We emphasize that this report reflects the authors' experience and opinions on the various classes of symptom-modifying medications, and is meant only as a guide to this controversial area of therapeutics. Although there are common physical features shared by every person who has FOP, there are differences among individuals that may alter the potential benefits or risks of any medication or class of medications discussed here. The decision to use or withhold a particular medication must ultimately rest with an individual patient and his or her physician.

Class I Medications: For acute flare-ups involving the major joints of the major appendicular skeleton, the immediate use of prednisone at a dose of 2 mg/kg/day (up to 100 mg) can be considered as a single daily dose for a maximum of four days. For maximal beneficial effect, the prednisone should be started within 24 hours of the onset of a flare-up, which corresponds to the earliest phase of acute and intense lymphocytic infiltration into skeletal muscle. If the flare-up is more than two days

old, prednisone is generally less effective. If the flare-up responds to the medication but recurs when the prednisone is discontinued, a repeat 4-day course with a subsequent 10-day taper can be considered. Prednisone should generally not be used for flare-ups on the chest or trunk, as it is difficult to judge the exact onset of a new flare-up. Prolonged or chronic use of corticosteroids is of no benefit, may accelerate heterotopic ossification (HO), is harmful systemically, and should not be considered. Furthermore, suppression of the pituitary-adrenal axis is likely to occur with chronic or long-term use and can have long-term harmful effects. The use of prednisone is meant only to suppress or abort the early inflammatory events of an acute FOP flare-up, and potentially suppress the subsequent death of skeletal muscle in the earliest stages of an FOP flare-up.

When the prednisone is discontinued (or if a flare-up existing for more than 48 hours is being considered for treatment), symptomatic treatment may be considered with a non-steroidal anti-inflammatory agent. A cyclooxygenase-2 (COX-2) inhibitor can be used instead of a traditional NSAID (Table 1). As with all non-steroidal anti-inflammatory medications, gastrointestinal precautions should prevail. If long-term use of the COX-2 inhibitors is considered, serum liver and kidney function tests should be monitored. COX-2 inhibitors should be used with caution in FOP patients with a history of cardiovascular disease or in older FOP patients who are severely immobilized or completely non-ambulatory.

Class II Medications can be considered with caution, at the physicians' discretion.

Class III Medications are under development and/or are being tested in clinical trials and are not yet available for general use.

VII. CLASSES OF MEDICATIONS (TABLE 1)

CLASS I MEDICATIONS

GENERIC	TRADE	CLASS	PROPOSED MECHANISM OF ACTION AS IT RELATES TO FOP	DOSING	MAJOR SIDE EFFECTS
Prednisone	Prednisone	Corticosteroid	<p>Decreases lymphocyte and macrophage recruitment and tissue infiltration; potent anti-inflammatory drug: Decreases inflammation, swelling and edema especially when involving jaw, throat, and major joints.</p> <p>Do not use for flare-ups involving chest or back (see text).</p>	<p>2 mg/kg once daily in AM by oral administration (PO) x 4 days maximum for acute flare-ups involving major joints. Flare-ups often result from over-use and soft tissue injuries. Prednisone – 1-2 mgs/kg, (per oral) once daily for 3-4 days to prevent flare-up after severe soft-tissue injury. Do not use after minor bumps or bruises. Use prednisone prophylactically as directed for dental or surgical procedures.</p> <p>Max dose: 100 mg/day. If flare-up recurs immediately, may repeat 4 day course with longer taper. May also use longer treatment with taper for flare-ups in the submandibular region, especially those that affect breathing or swallowing. Should be started within 24 hours of the onset of a flare-up for maximal effectiveness. (Medication should be taken with food).</p> <p>FOR PATIENTS IN INDIGENOUS REGIONS, ANTI-PARASITIC PRECAUTIONS MAY BE NECESSARY -----</p> <p>Alternatively, high dose intravenous corticosteroid (methylprednisolone or prednisolone) therapy may be considered, but must be performed during an inpatient hospitalization to monitor for potentially dangerous side-effects of hypertension. The standard protocol for IV corticosteroid therapy is as follows: 7-15 mg/kg of methylprednisolone or 20-30 mg/kg of prednisolone IV daily on three consecutive days.</p> <p>Some prefer to administer it on alternate days as some patients tolerate it better. For example:</p> <p>Day 1: 20-30 mg/kg of prednisolone IV Day 2: No medication Day 3: 20-30 mg/kg of prednisolone IV Day 4: No medication Day 5: 20-30 mg/kg of prednisolone IV.</p> <p><u>Total daily dose not to exceed 1000 mg.</u></p>	<ul style="list-style-type: none"> ~ avascular necrosis of hip ~ diabetes-cataracts ~ osteoporosis - Cushing's disease ~ chronic dependency ~ immune suppression ~ adrenal suppression ~ growth retardation ~ acne ~ peptic ulcers ~ hypertension ~ glaucoma ~ weight gain ~ skin bruising ~ sleep and mood disturbance

VII. CLASSES OF MEDICATIONS (TABLE 1)

CLASS I MEDICATIONS

GENERIC	TRADE	CLASS	PROPOSED MECHANISM OF ACTION AS IT RELATES TO FOP	DOSING	MAJOR SIDE EFFECTS
Ibuprofen	Advil Motrin	Non-steroidal anti-inflammatory medication (non-specific cox-1 and cox-2 inhibitor)	Anti-inflammatory and anti-angiogenic; symptomatic relief during a flare-up; Potential use in prevention by inhibiting production of inflammatory prostaglandins	Peds: 4-10 mg/kg PO every 6 hrs, as needed. Adult: 200-800 mg PO every 6 hrs, as needed. (Medication should be taken with food).	~ gastrointestinal bleeding ~ impaired renal function
Indomethacin	Indocin	Non-steroidal anti-inflammatory medication (non-specific Cox-1 and Cox-2 inhibitor)	Anti-inflammatory and anti-angiogenic; symptomatic relief during a flare-up; Potential use in prevention by inhibiting production of inflammatory prostaglandins	Peds: 2-4 mg/kg/day PO; or 150-200 mg/day (whichever is less); divided tid Adult: 50 mg PO tid or Indocin – SR (sustained release) at a dose of 75 mg. PO bid. (Medication must be taken with food).	~ gastrointestinal bleeding ~ impaired renal function
Celecoxib	Celebrex	Cyclo-oxygenase-2 inhibitor	Anti-inflammatory and potent anti-angiogenic; symptomatic relief during a flare-up; Potential use in prevention by inhibiting production of inflammatory prostaglandins	Peds and Adults: 100-200 mg po bid for maintenance, at discretion of M.D. -For acute & chronic flare-ups, not to exceed maximum anti-angiogenic dose of 250 mgs/M ² PO bid <u>or</u> 6 mg/kg PO bid (whichever is lower; rounded-up or rounded-down to the closest multiple of 100 mg) and not to exceed a maximum total daily dose of 600 mgs. for more than 16 months. Medication should be taken with a fatty snack for maximum absorption. Although used compassionately in children, not yet approved for pediatric use. -Patients should be monitored for adequate hepatic and renal function. -Use with caution in FOP patients with a history cardiovascular disease or in older FOP patients who are severely immobilized or completely non-ambulatory. - MUST NOT BE TAKEN BY PATIENTS WHO ARE ALLERGIC TO SULFONAMIDES OR BY PATIENTS WITH ASPIRIN-SENSITIVE ASTHMA.	~ gastrointestinal bleeding ~ impaired renal function ~concern about cardiovascular and cerebrovascular risks ~NOT TO BE TAKEN BY PATIENTS WITH KNOWN ALLERGIES TO SULFONAMIDES OR BY PATIENTS WITH ASPIRIN-SENSITIVE ASTHMA

VII. CLASSES OF MEDICATIONS (TABLE 1)

CLASS II MEDICATIONS

GENERIC	TRADE	CLASS	PROPOSED MECHANISM OF ACTION AS IT RELATES TO FOP	DOSING	MAJOR SIDE EFFECTS
Montelukast	Singulair	Leukotriene receptor antagonist	Blocks inflammatory mediators; complementary action to cyclo-oxygenase inhibitors.	Peds (2-5 yo): 4 mg PO at bedtime 6-14 yo: 5 mg PO at bedtime Adults: 10 mg PO at bedtime	Generally well-tolerated. Rarely: angioedema, headache, flu-like syndrome, fatigue, abdominal pain; possible association with behavior/mood changes, suicidal thinking and behavior, and suicide. Patients should be monitored for changes in behavior and mood.
Cromolyn	Gastrocrom	Mast cell Stabilizer	Reduces mast cell degranulation, but poorly absorbed from GI tract. May be more effective if used chronically	Peds (0-2 yo): 20 mg/kg/d PO div qid; (2-12 yo): 100 mg PO qid Adult: 200 mg PO qid	Generally, extremely well-tolerated. Rarely: throat Irritation, dry throat, cough, bitter taste.
Pamidronate	Aredia	Amino-bisphosphonate	Anti-angiogenic; possibly anti-inflammatory; potential inhibition of early angiogenic fibroproliferative lesion; well-established effects on decreasing bone remodeling in normotopic skeleton and in protecting normotopic skeleton from profound osteopenic effects of chronic intermittent high dose glucocorticoids.	<p>Peds (2-3 yo): 0.75 mg/kg/day by slow IV infusion for three days;</p> <p>For children older than 3 yo and for adolescents and adults: 1.0 mg/kg/day for three days. Medication should be infused slowly each day over 4-5 hours.</p> <p>Note: On the first day of the first cycle of treatment, the patient must receive half the dose. In case of fever, give standard acetaminophen treatment. The 3-day cycle of treatment should be repeated no more than 4 times annually. For dilution instructions, see text.</p> <p>Patients should have the following blood tests checked prior to Pamidronate treatment: serum calcium, phosphate albumin, alkaline phosphatase, 25-hydroxyvitamin D, BUN, creatinine, CBC.</p> <p>All patients should receive adequate supplemental dietary calcium and vitamin D daily during and indefinitely following Pamidronate treatment.</p>	Generally well-tolerated. Contraindicated in renal dysfunction. An acute phase reaction characterized by fever, malaise, and myalgia occurs commonly during IV infusion of Pamidronate and may persist for 18-24 hours. Pre-treatment with acetaminophen may lessen symptoms. In case of fever or other symptoms of acute phase reaction, give standard acetaminophen treatment. Pamidronate should not be used in patients who are hypocalcemic as tetany may result, and subsequent management of hypocalcemia can be very difficult in patients with FOP. Daily oral calcium and vitamin D supplementation should be provided to all patients who receive Pamidronate (not just on days of infusion, but daily on a continual basis for at least two weeks). Frequent high-dose use of aminobisphosphonates in children can lead to osteopetrosis and possibly low energy femoral fractures. <i>See also cautions in text for osteonecrosis of jaw.</i>

VII. CLASSES OF MEDICATIONS (TABLE 1)

CLASS II MEDICATIONS

GENERIC	TRADE	CLASS	PROPOSED MECHANISM OF ACTION AS IT RELATES TO FOP	DOSING	MAJOR SIDE EFFECTS
Pamidronate (Continued)				<p>Photographs and clinical measurements of the flare-up should be obtained prior to treatment and daily thereafter for 14 days.</p> <p>Plain radiographs of the affected area should be obtained prior to treatment and 6 weeks thereafter to document the formation of any heterotopic ossification</p>	
Zoledronate	Zometa	Amino-bisphosphonates	Anti-angiogenic; possibly anti-inflammatory; potential inhibition of early angiogenic fibroproliferative lesion; well-established effects on decreasing bone remodeling in normotopic skeleton and in protecting normotopic skeleton from profound osteopenic effects of chronic intermittent high dose glucocorticoids.	<p>Adult (18.y.o and older): 5 mg by slow IV infusion over 30 minutes. Not for use in children.</p> <p>Patients should have the following blood tests checked prior to Zoledronate treatment: serum calcium, phosphate albumin, alkaline phosphatase, BUN, creatinine, CBC.</p> <p>All patients should receive adequate supplemental dietary calcium and vitamin D daily during and indefinitely following Pamidronate treatment. Photographs and clinical measurements of the flare-up should be obtained prior to treatment and daily thereafter for 14 days. Plain radiographs of the affected area should be obtained prior to treatment and 6 weeks thereafter to document the formation of any heterotopic ossification.</p>	<p>Generally well-tolerated. Contraindicated in renal dysfunction/ An acute phase reaction characterized by fever, malaise, and myalgia occurs commonly during IV infusion of Zoledronate and may persist for 18-24 hours.</p> <p>Pre-treatment with acetaminophen may lessen symptoms. In case of fever or other symptoms of acute phase reaction, give standard acetaminophen treatment.</p> <p>Zoledronate should not be used in patients who are hypocalcemic as tetany may result, and subsequent management in patients with FOP can be very difficult. Daily oral calcium and vitamin D supplementation should be provided to all patients who receive Zoledronate (not just on days of infusion, but daily on a continual basis for at least two weeks). Frequent high-dose use of aminobisphosphonates in children can lead to osteopetrosis and possibly low-energy femoral fractures. See also cautions in text for osteonecrosis of jaw.</p>
Imatinib	Gleevec	Selective Tyrosine Kinase inhibitor	Off-target effects of blocking c-Kit, HIF1- α , PDGFR α , and multiple MAP kinases	<p>Children and Adolescents: Oral: 340 mg/m²/day administered once daily; maximum daily dose: 600 mg/day.</p> <p>Adults: 400 mg once daily; may be increased to 600 mg daily; an increase to 800 mg daily has been used.</p> <p>Dose adjustments for renal and hepatic impairments, hematologic toxicity and non-hematologic toxicities.</p>	<p>No randomized placebo-controlled trials have been conducted to date to demonstrate efficacy; one case series suggests there may be benefits for decreasing intensity of flares, but data are anecdotal.</p>

VII. CLASSES OF MEDICATIONS (TABLE 1)

CLASS II MEDICATIONS

GENERIC	TRADE	CLASS	PROPOSED MECHANISM OF ACTION AS IT RELATES TO FOP	DOSING	MAJOR SIDE EFFECTS
Imatinib (Continued)				Imatinib should always be prescribed under the guidance of an adult or pediatric oncologist or rheumatologist.	<p>Most Common Side-effects:</p> <p>Bone marrow suppression: May cause bone marrow suppression (anemia, neutropenia, and thrombocytopenia), usually occurring within the first several months of treatment. Median duration of neutropenia is 2 to 3 weeks; median duration of thrombocytopenia is 2 to 4 weeks. Monitor blood counts weekly for the first month, biweekly for the second month, and as clinically necessary thereafter.</p> <p>Fluid retention/edema: Imatinib is commonly associated with fluid retention, weight gain, and edema (risk increases with higher doses and age >65 years)</p> <p>GI toxicity: Imatinib is associated with a moderate emetic potential; antiemetics may be recommended to prevent nausea and vomiting. May cause GI irritation; take with food and water to minimize irritation.</p> <p>Hepatotoxicity: Hepatotoxicity may occur; Monitor liver function (transaminases, bilirubin, and alkaline phosphatase) prior to initiation and monthly, or as needed thereafter.</p> <p>Nephrotoxicity: Imatinib is associated with a decline in renal function; may be associated with duration of therapy</p>

VII. CLASSES OF MEDICATIONS (TABLE 1)

CLASS III MEDICATIONS

GENERIC	TRADE	CLASS	PROPOSED MECHANISM OF ACTION AS IT RELATES TO FOP	DOSING	MAJOR SIDE EFFECTS
ACVR1/ALK2 Signal Transduction Inhibitor (STI)	Saracatinib (Astra Zeneca; STOPFOP Investigators); IPN60130 (Ipsen); BCX9250 (Bio Cryst); INCB000928 (Incyte); Ker-047 (Keros)	Signal Transduction Inhibitor	Blocks ACVR1/ALK2 signal transduction	Not applicable at present time; Ongoing clinical trials for all compounds	See: www.clinicaltrials.gov ; www.ifopa.org/ongoing_clinical_trials_in_fop
Monoclonal Antibody Against ACVR1/ALK2	DS-6016 (Daiichi-Sankyo)	ALK2 Antibody	Blocks ACVR1/ALK2 at cell surface	Not applicable at present time	Not yet determined
mTOR Inhibitors	Rapamycin (Kyoto University)	mTOR Inhibitor	Inhibits ACVR1/ALK2 signal transduction	Not applicable at present time; Ongoing Phase II Clinical Trial	Not yet determined
Monoclonal Antibody Against Activin A	Garetosmab (Regeneron)	Activin A Antibody	Blocks Activin A signaling through mutant ACVR1/ALK2	Not applicable at present time; Ongoing Phase III Clinical Trial	See: www.clinicaltrials.gov ; www.ifopa.org/ongoing_clinical_trials_in_fop
Retinoic Acid Receptor- γ Agonists	Palovarotene (Ipsen)	RAR- γ Agonist	Inhibits Ectopic Chondrogenesis	Not applicable at present time; Ongoing Phase III Clinical Trial	See: www.clinicaltrials.gov ; www.ifopa.org/ongoing_clinical_trials_in_fop

VIII. EMERGENCY GUIDELINES FOR 1st RESPONDERS, PHYSICIANS & DENTISTS

1. Avoid all IM injections unless necessary for survival of the patient. They will likely cause flare-ups and subsequent ossification.
2. Peripheral IVs are permissible. Use smallest needle possible with brief tourniquet time. Avoid repeated tourniquet use or over-inflation of blood pressure cuffs.
3. Avoid central venous access.
4. In case of major trauma, begin corticosteroids immediately (oral) or IV equivalent of oral Prednisone - 1-2 mg/kg once daily for 4 days.
5. Pad all bony prominences to prevent pressure ulcers and skin breakdown.
6. The cervical spine is often partially or completely ankylosed from FOP. Do not manipulate.
7. The jaw is likely limited in movement or functionally ankylosed. Even if it is mobile, it is extremely susceptible to trauma. Do not passively manipulate. Over-stretching and mandibular blocks are forbidden as they will cause flare-ups.
8. Flare-ups of the anterior neck can compromise breathing and swallowing and should be considered a medical emergency. These submandibular flare-ups require early identification. Provide high dose steroids immediately (methylprednisolone 100 mg iv or Dexamethasone 4 mg iv). Avoid additional trauma with lesional manipulation. Airway monitoring, aspiration precautions, nutritional support, immediate use of corticosteroids.
9. Head and neck injuries are common from falls as the arms are rigid from ankylosis of the shoulders early in life and cannot be used to protect the head in case of falls.
10. With head injury, always brace the neck.
11. With any head injury, even without loss of consciousness, a head CT is mandatory to rule out intracranial bleeding due to the high likelihood of an unprotected impact.
12. Flare-ups of the head in younger patients can appear as very large scalp swellings and initially disfiguring. A conservative approach should be taken with scalp flare-ups, with monitoring, and pain control if necessary. Scalp flare-ups will resolve spontaneously over time and disfigurement will be minimal to none as new ossifications are incorporated into the growing skull.
13. Facial swelling due to scalp flare-ups in FOP is uncommon, and other etiologies for facial swelling should be considered. A brief course of antihistamine should be considered to exclude allergies in FOP patients who present with facial swelling.
14. For “dirty” or contaminated wounds use tetanus hyperimmune globulin. Avoid tetanus immunization as IM or subcutaneous immunization unless necessary, as this has a high likelihood of inciting a flare-up.
15. Some hearing impairment is common in FOP. Speak loudly and clearly.
16. Although stable hearing loss is a common feature of FOP in children, acute hearing loss and ear pain is not and should be evaluated and treated as in any child.
17. Dental pain is a common issue in FOP patients and must be evaluated and treated promptly, but only after thorough consultation with an FOP dental expert. Overstretching of the jaw and mandibular blocks are forbidden.
18. Kidney stones are common in adults with FOP. Keep well hydrated.

19. Fractures are common in normotopic as well as heterotopic bone. Closed immobilization with splinting and bracing are recommended. Open reduction is contraindicated unless thoroughly discussed with an FOP specialist.
20. With nausea and vomiting in individuals with an ankylosed jaw, cover empirically with antibiotics for aspiration pneumonia.
21. Acute and often severe limb swelling can be seen with flare-ups of FOP, especially of the lower extremities. Due to intense inflammation, angiogenesis and capillary leakage, this swelling may grow to extraordinary and alarming size and lead to extravascular compression of nerves and tissue lymphatics. After excluding a possible deep vein thrombosis, the swelling should be treated conservatively with adequate pain control, elevation, and ultimately with safe lymphedema manipulations. Although signs and symptoms of compartment syndrome may prompt consideration of emergent surgical release of pressure, this will exacerbate the flare-up and **MUST** be avoided.
22. In the case of limb swelling that prompts concern for deep vein thrombosis, Doppler ultrasound evaluation of the venous system may be indicated.
23. Ask if patient is enrolled in any FOP Clinical Trials and communicate with principal investigator and regional FOP specialist.
24. In the case of choking and failure to clear throat manually, perform Heimlich maneuver if there is no evidence for abdominal heterotopic bone that would prevent attempts.
25. Chest compressions will likely be futile. The chest wall is rigid and immobile.
26. Intubation must be through an awake, fiberoptic nasotracheal approach by an experienced anesthesiologist.
27. If an emergency tracheotomy is necessary in an individual with anterior neck ossifications, a dental or other drill may be necessary to create an airway.
28. In emergency situations where patients have difficulty clearing secretions, use bronchodilators, mucolytics, and guaifenesin, with a low threshold for mechanical insufflation-exsufflation devices. Hydration should be optimized with intravenous fluids.

For Consultation on FOP Anesthesia & Airway Issues:

Zvi Grunwald, MD

The James D. Wentzler Professor and Chairman Emeritus

Department of Anesthesiology

Thomas Jefferson University

111 South 11th Street, Suite G-8490

Philadelphia, PA 19107, USA

Tel: 215-955-6161

Cell: 215-206-7362

Fax: 215-923-5507

Email: zvi.grunwald@jefferson.edu

For Consultation on Emergent Dental Care:

Corrie Crowe, DDS

1793 Springdale Road

Cherry Hill, NJ 08003, USA

Tel: 856-258-4025 (Staff Assistant: Lynn)

Cell: 407-701-3210

Fax: 856-504-6179

Email: drcrowedentistry@gmail.com

Clive S. Friedman, DDS, FAAPD

389 Hyde Park Road

London, Ontario

Canada N6h 3R8

Phone: cell 519 6576014

Office: 519-679-9860; (private line): 519-679-5473

Home: 519 438-1198

Email: clive@dentistryforkids.ca for (home) clivesf@mac.com

For Hospital Dentistry and Dental Surgery:

Robert Diecidue, MD, DMD, MBA, MPH

Thomas Jefferson University

Jefferson Medical College

Department of Oral and Maxillofacial Surgery

Chairman and Professor

909 Walnut Street - Suite 300

Philadelphia, Pennsylvania 19107, USA

Tel: 215-955-6215; 215 955 5131

Fax: 215-923-9189

Email: robert.diecidue@jeffersonhospital.org

IX. CONCLUSIONS

A physician treating a patient with FOP must never withhold an available medication or treatment that may be truly helpful, but those medications must also be tested with scientific clarity to determine if they are, in fact, truly helpful or just simply the products of wishful thinking. As the Roman dramatist Terence warned more than two thousand years ago, “One easily believes what one earnestly hopes for.”

In the absence of clear evidence-based research from controlled clinical trials, it is difficult to advocate a particular therapy with enthusiasm. Although it is appealing to attempt to swim across multiple therapeutic currents to safety, the waters of FOP are deep and dangerous. The carefully designed and well-controlled clinical trial may ultimately be the safest bridge across these troubled waters of FOP. Such an approach will require the patience and fortitude of the entire FOP community.

In the meanwhile, the physician caring for a patient with FOP must constantly review evolving scientific information and chart the safest, most compassionate and most responsible course for the patient until the enduring bridges are built and their safety and efficacy verified.

X. ACKNOWLEDGMENTS

The authors thank Mrs. Karen Kirchoff for her invaluable assistance in assembling the section on Aids, Assistive Devices & Adaptations, and Mrs. Kamlesh Rai for her diligent help and extensive support in the preparation and revision of this document.

This work was supported in part by The Ian Cali Endowment, The International FOP Association, The Center for Research in FOP and Related Disorders, The Weldon Family Endowment, The Isaac & Rose Nassau Professorship of Orthopaedic Molecular Medicine, The Cali-Weldon Professorship of FOP Research, The Robert & Arlene Kogod Professorship, and the Friends and Families of FOP patients worldwide.

The authors thank the Center for Research in FOP & Related Disorders at the University of Pennsylvania for supporting the International Clinical Council for FOP (ICC).

XI. CONFLICTS OF INTEREST DECLARATION

GB, CLDC, PD, EMWE, ECH, NH, FSK, RK, MAM, JCN, RJP, MDR and MAZ receive clinical trials research funding from Ipsen/Clementia Pharmaceuticals.

RJD and RM are consultants for Ipsen/Clementia Pharmaceuticals.

MAZ is on the data safety monitoring board for Ipsen/Clementia Pharmaceuticals.

EMWE, ECH, RK, FSK, MAM, RJP and MDR receive clinical trials research funding from Regeneron Pharmaceuticals.

RM is a paid consultant for Regeneron Pharmaceuticals.

GB, CLDC, PD, EMWE, NH, ECH, FSK, RK, RM, JCN, RJP, MDR, CS, MAZ and KZ serve as unpaid volunteers on the IFOPA Medical Registry Advisory Board.

EMWE, ECH, RJP and FSK serve as unpaid volunteers on the FOP Biomarker Consortium.

ECH serves as an unpaid volunteer on the Fibrous Dysplasia Foundation Medical Advisory Board.

MDR is a consultant and/or speaker for Sanofi-Genzyme, Shire, Alexion, Biomarin, Chiesi, Ipsen/Clementia Pharmaceuticals, and Regeneron Pharmaceuticals and receives clinical trial research support from Sanofi-Genzyme, Alexion and Enzyvant.

AC is a trustee of the Radiant Hope Foundation and trustee of the Ian Cali FOP Research Fund - PENN Medicine - Center for Research in FOP & Related Disorders, and is an unpaid volunteer with Ipsen/Clementia Pharmaceuticals Burden of Illness Advisory Group.

PD is an unpaid medical advisor for FOP Brazil.

MAM and MAZ are nonpaid consultants for BioCryst.

EMWE is an advisor for AstraZeneca and Ipsen Pharmaceuticals.

RK receives research support from UltraGenyx; is a paid consultant for Ipsen/Clementia Pharmaceuticals, Regeneron Pharmaceuticals, UltraGenyx, Internis, and Alexion; and is a nonpaid member of the Medical Advisory Board for the UK Brittle Bone Society.

XII. AUTHORS' CONTACT INFORMATION

(*Member of the ICC)

***Mona Al Mukaddam, MD, MS, CCD**

Assistant Professor of Clinical Medicine
Division of Endocrinology, Diabetes and Metabolism;
Ian Cali Clinical Scholar in FOP, Department of Orthopaedic Surgery,
The Perelman School of Medicine - The University of Pennsylvania
Penn Medicine University City
3737 Market Street, 3rd floor
Philadelphia, PA 19104, USA
Tel: 215-294-9702
Fax: 215-243-4664
Email: Mona.AIMukaddam@pennmedicine.upenn.edu

***Genevieve Baujat, MD**

Centre de Référence Maladies Osseuses Constitutionnelles
Département de Génétique
Hôpital Necker-Enfants Malades
Paris, France
Tel: (secretariat): 0033444495153
Office: 003371196418
Email: genevieve.baujat@nck.aphp.fr

***Matthew Brown, MBBS, MD, FRACP, FAHMS, FAA (Emeritus)**

Professor of Medicine
King's College London
Director
Guy's and St Thomas' NHS Foundation Trust and
King's College London NIHR Biomedical Research Centre
Guy's Hospital, 8th Floor Tower Wing
Great Maze Pond, London SE1 9RT, U.K.
Email: matt.brown@kcl.ac.uk

Amanda Cali (Ex officio)

Email: Akanga41@gmail.com

***Tae-Joon Cho, MD**

Professor
Division of Pediatric Orthopaedics
Seoul National University Children's Hospital
101 Daehang-ro Jongno-gu
Seoul 110-744, Republic of Korea
Tel: +82-2-2072-2878
Fax: +82-2-745-3367
Email: tjcho@snu.ac.kr; tjcho.pos@gmail.com

Corrie Crowe, DDS
1793 Springdale Road
Cherry Hill, NJ 08003, USA
Tel: 856-258-4025 (Receptionist: Lynn)
Cell: 407-701-3210
Fax: 856-504-6179
Email: drcrowdentistry@gmail.com

***Carmen L. De Cunto, MD**
Professor and Chief
FOP Clinical Advisor, Argentina
Pediatric Rheumatology Section
Department of Pediatrics
Hospital Italiano de Buenos Aires
Gascón 450, 1181
Ciudad Autónoma de Buenos Aires, Argentina
Tel: +5411-4959-0578
Fax: +5411-4959-0577
Email: carmen.decunto@hospitalitaliano.org.ar

***Patricia L.R. Delai, MD**
Hospital Israelita Albert Einstein
Instituto de Ensino e Pesquisa
Office: Rua Pedro de Toledo 129 cj 121- Vila Clementino
Cep-04039-001
São Paulo-SP, Brazil
Tel: +55-11-99394-5848
+55-11-99658-8816
Email: patricia.delai@einstein.br; patricia.delai@gmail.com

***Robert J. Diecidue, DMD, MD, MBA, MPH**
Professor and Chair
Sidney Kimmel Medical College
Thomas Jefferson University
909 Walnut Street – Floor 3,
Philadelphia, PA 19107, USA
Tel: 215 955 6215; 215 955 5131
Fax: 215 923 9189
Email: Robert.Diecidue@jefferson.edu

***Maja DiRocco, MD**
Head, Unit of Rare Diseases
Department of Pediatrics
IRCCS Giannina Gaslini Institute
Via Gerolamo Gaslini 5
16147 Genoa, Italy
Tel: +39-010-563-6794
Fax: +39-010-563-6211
Email: Majadirocco@gaslini.org

***Elisabeth Marelise W. Eekhoff, MD, PhD**

Amsterdam University Medical Centers (Amsterdam UMC) location
VU University Medical Center (VUMC) Amsterdam
Department of Internal Medicine/Section Endocrinology
De Boelelaan 1117
1081HV Amsterdam, The Netherlands
Tel: +31-20-4440588 or +31-622959618
Email: emw.eekhoff@vumc.nl

***Clive S. Friedman, BDS (Diplomate AAPD)**

Asst. Clinical Prof Schulich School of Medicine and Dentistry
Pediatric Oral Health and Dentistry
389 Hyde Park Road
London, Ontario N6H 3R8, Canada
Tel: 519-679-9860
Cell: 519-657-6014
Personal Email: clivesf@mac.com
Hospital email: Clive.Friedman@lhsc.on.ca

***Zvi Grunwald, MD**

The James D. Wentzler Professor and Chairman Emeritus
Department of Anesthesiology
Thomas Jefferson University
111 South 11th Street, Suite G-8490
Philadelphia, PA 19107, USA
Tel: 215-955-6161; Cell: 215-206-7362
Fax: 215-923-5507
Email: zvi.grunwald@jefferson.edu

***Nobuhiko Haga, MD**

Professor
Director
Rehabilitation Services Bureau
National Rehabilitation Center for Persons with Disabilities
4-1 Namiki, Tokorozawa City,
Saitama Pref. 359-8555, Japan
Tel: +81-4-2995-3100, Fax: +81-4-2995-3672
Email: haga-nobuhiko@rehab.go.jp

***Edward Hsiao, MD, PhD**

Department of Endocrinology, Faculty Practice
University of California-San Francisco
400 Parnassus Ave., 5th Floor A550
UCSF Box 1222
San Francisco, CA 94143-1222, USA
Tel: 415-353-2350; Office phone (for research-related questions): 415- 476-9732
Email: edward.hsiao@ucsf.edu

***Frederick S. Kaplan, MD**

Isaac and Rose Nassau Professor of Orthopaedic Molecular Medicine
Co-Director, Center for Research in FOP & Related Disorders
The Perelman School of Medicine - The University of Pennsylvania
Department of Orthopaedic Surgery
3737 Market Street – Sixth Floor
Philadelphia, PA 19104, USA
Tel: (office) 215-294-9145
Fax: 215-222-8854
Email: Frederick.Kaplan@penmedicine.upenn.edu

***Dr. Richard Keen, BS, PhD, FRCP**

Rheumatologist & Honorary Senior Lecturer in Metabolic Bone Disease
The Royal National Orthopaedic Hospital
Stanmore, Middlesex HA7 4LP
United Kingdom
Tel: +44 (0)20 3947 0056 (option 3 - Secretaries)
Fax: +44 (0)20 8420 7487
Email: richard.keen1@nhs.net; DrRichardKeen@aol.com

Additional contact for Dr. Richard Keen:

Janice Cohen
Secretary to Dr Richard Keen/Dr Judith Bubbear
Centre for Metabolic Bone Disease
Royal National Orthopaedic Hospital
Brockley Hill, Stanmore, Middlesex HA7 4LP, United Kingdom
Tel: +44(0)20 3947 0056
Email: Janice.cohen@nhs.net

Joseph A. Kitterman, MD

Professor Emeritus
Department of Pediatrics and Cardiovascular Research Institute
U-503, Box 0734
University of California San Francisco
San Francisco, CA 94143-0734, USA
Email: jkitter81@gmail.com

Charles Levy, MD

Chief, Physical Medicine and Rehabilitation Service
North Florida/South Georgia Veterans Health Service
Adjunct Associate Professor, Department of Occupational Therapy
Research Scholar, Center for Arts in Medicine
University of Florida
1601 S.W. Archer Road
Gainesville, Florida 32608, USA
Tel: 800 324 8387 Ext 6922
Fax: 352-374-6167
Email: levyce@aol.com

***Dr. Vrisha Madhuri**

Professor Orthopaedics, Adjunct Scientist Center for Stem Cell Research
Department Paediatric Orthopaedics
Ida Scudder Chair for Clinical Research
Christian Medical College Hospital
Vellore 632004, India

The alternative address is:

Lab 4, Centre for Stem Cell Research
Christian Medical College
Vellore 632002, India

Email:

madhuriwalter@cmcvellore.ac.in

madhuriwalter@hotmail.com

madhuriortho@gmail.com

***Rolf Morhart, MD**

Department of Pediatrics
Klinikum Garmisch- Partenkirchen
Auenstr.6
D- 82467 Garmisch- Partenkirchen, Germany

Tel: +49-(0)8821-58889

Fax: +49-(0)8821-77-1351

Email: rmorhart@web.de

***J. Coen Netelenbos, MD, PhD**

Professor Emeritus Endocrinology
Amsterdam University Medical Center (Amsterdam UMC)
Location VU University Medical Center (VUMC) Amsterdam
Department of Internal Medicine/ Section Endocrinology
University Hospital Vrije Universiteit
De Boelelaan 1117, 1081HV Amsterdam, The Netherlands
Tel: +31-20-444-0530
Cell: +31 62-128-2918
E-mail: cnetelen@planet.nl; c.netelen@amsterdam.umc.nl

***Robert J. Pignolo, MD, PhD**

Chair, Division of Geriatric Medicine & Gerontology
Robert and Arlene Kogod Professor of Geriatric Medicine
Mayo Clinic College of Medicine
200 First Street, SW
Rochester, MN 55905, USA
Tel: 507-293-0813
Fax: 507-293-3853
Email: Pignolo.robert@mayo.edu

***Christiaan Scott, MBChB, FCPaed (SA)**

Paediatric Rheumatologist
Red Cross Children's Hospital
University of Capetown
Cape Town 7700, South Africa
Tel: +27-21-6585191
Cell: +27845805473
Email: chris.scott@uct.ac.za

Eileen M. Shore, PhD

Cali-Weldon Professor of FOP Research
University of Pennsylvania
Department of Orthopaedics
309A Stemmler Hall
3450 Hamilton Walk
Philadelphia, PA 19104-6081, USA
Phone: 215-898-2331; Fax: 215-573-2133
Email: shore@penncmedicine.upenn.edu*

***Michael Zasloff, MD, PhD**

Adjunct Professor
Departments of Orthopaedic Surgery and Genetics
The Center for Research in FOP & Related Disorders
The University of Pennsylvania School of Medicine
and
Professor, Departments of Surgery and Pediatrics
Director, Surgical Immunology
Georgetown University
Med/Dent NW 210
Washington, DC 20007, USA
Tel: 202-687-5707 (office) or
Home: 610-617-3488
Cell: 484-433-7807
Fax: 202-687-0992
Email: maz5@georgetown.edu or mzasloff@aol.com

***Keqin Zhang, MD, PhD**

Director, Department of Endocrinology
Tongji Hospital
Shanghai Tongji University
389. Xin Cun Road
Shanghai 200065, P.R. China
Email: keqzhang2007@126.com

Figure 1. Targets & Potential Treatments for FOP

